

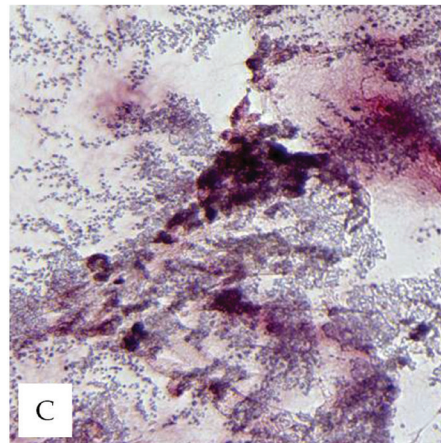
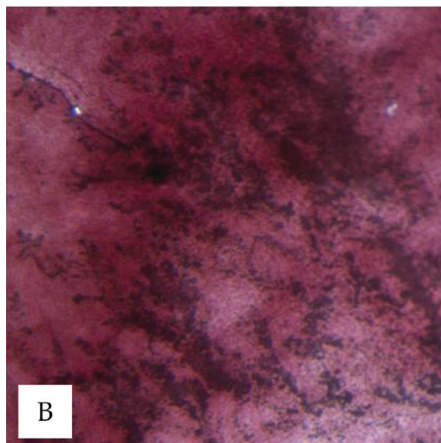
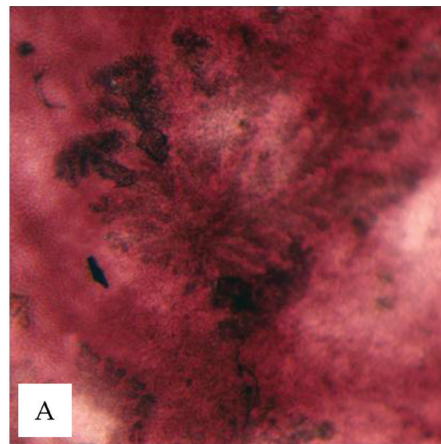
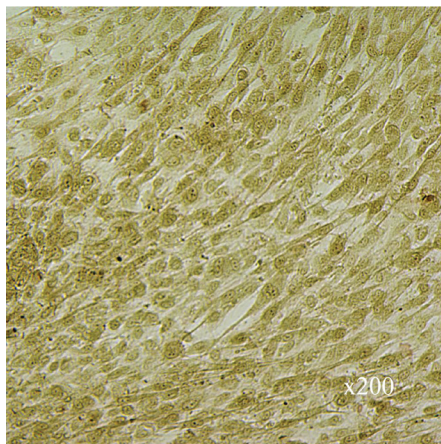
E  
SP

Endodontic Society of the Philippines

# Journal



July 2018 . Volume 11, Number 1  
ISSN 2094-3903



Official Journal of the Endodontic Society of the Philippines

# CONTENTS

Regenerative Endodontics	<i>1</i>
Management of Endodontic Emergencies: Pulpotomy Versus Pulpectomy	<i>7</i>
The Role of Calcium Hydroxide in the Healing of Periapical Lesion: A Case Report	<i>14</i>
Case Report: Management of Mandibular Lateral Incisors with Vertucci Type II Canal Configuration	<i>19</i>
Influence of Root Canal Sealers in Calcification	<i>24</i>

## EDITORIAL BOARD

Illuminada L. Vilorio, DMD, PhD  
EDITOR-IN-CHIEF

Emabel S. Jugo, DDM | Grace Ellen S. Dey, DMD, MScD | Valery C. Virata, DMD  
MEMBERS

---

Disclaimer: The statements, opinions in this journal are solely of those of individuals, authors, contributors, editors are indicated. Those statements and opinions do not reflect any endorsement by the Endodontic Society of the Philippines or its agents, authors, contributors and editor. Unless otherwise specified, the Endodontic Society of the Philippines disclaim any and responsibility of liability for such material.

---

# The ESP Journal Guidelines for Authors

*The ESP Journal* is a refereed journal. All submissions undergo initial review by one member of the editorial board and if approved, will be advanced to the rest of the editorial board for further peer-review.

*The ESP Journal* provides detailed information about the review and publication process.

## I. Authorship, Copyright, and Permissions

- *The ESP Journal* defines “authors” as those individuals who have been involved in the preparation of a manuscript and not all individuals who may have been involved in the project or program the manuscript discusses. The latter individuals should be acknowledged in an “Acknowledgments” section. For manuscripts with co-authors, the order would be: the first name of author to appear is the main author of the manuscript, followed by co-author/s who have contributed in the preparation of the paper itself.
- All submissions to *The ESP Journal* must be an original work of the author/s listed and must not have been previously published in another journal. An author submitting a manuscript that includes material that has been reproduced or adapted from a copyrighted source is responsible for obtaining any necessary permission from the copyright owner and acknowledging accordingly in the manuscript that such permission was obtained.
- “Authorized Reprinted Articles” pertain to those papers that have been published in another journal and has granted *The ESP Journal* the permission to re-publish said articles in verbatim. Proper acknowledgement of the original authors and publishing journal should be present in the paper.
- *The ESP Journal* highly observes “writing ethics”. Any mode of plagiarism in a submitted article will not be tolerated and such articles will be rejected by the editorial board.

## II. Manuscript Format Considerations

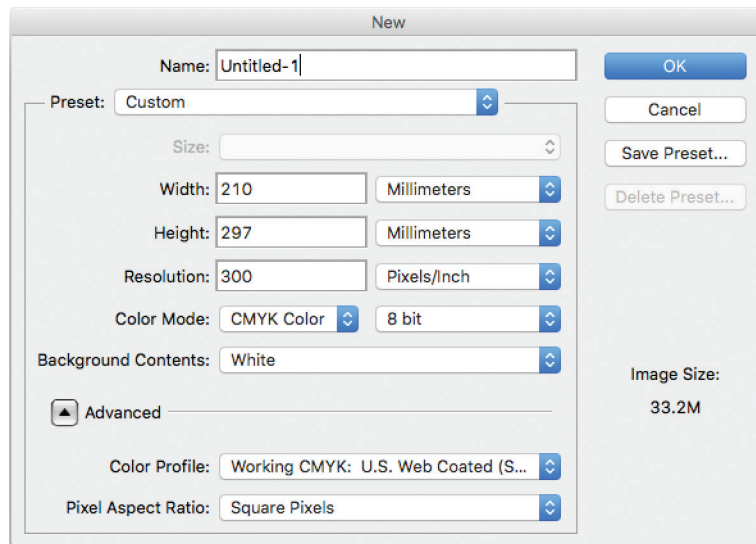
All submissions to *The ESP Journal* should be in Microsoft Word file. Additional format considerations are as follows:

- Text should be one font, font size, and font color.
- Paragraphs should be left aligned, not indented, and single-spaced, with one line of space between paragraphs.
- Tables and figures should be positioned at the appropriate places within the body of the manuscript.
- HTML formats are not acceptable, and *The ESP Journal* does not support other web enhancements, including such formats as multimedia (sound/video).

## III. Manuscript Structure Considerations

### A. Organization of Original Research Manuscripts:

1. Title: The title should have no abbreviations. It is important that the title is attention-catching and is reflective of the content and topic.
2. Authors Information: The entry for author information should be: full name, title, and institutional affiliations (Position, Name of Institution, Department/College, City, Country)
3. Abstract: The abstract is a concise description of the problem, hypothesis, methods, results, and conclusion. It should be no more than 250 words and is in bold format. 2-3 keywords may follow the abstract.
4. Introduction: This section should entice readers by describing the need for bridging the gap of a particular knowledge. A few relevant review of literature and historical background of the problem covers this section.
5. Materials and Methods: Materials and methods should all be described in paragraph form. No bullets are accepted.
6. Results: Relevant Figures and Tables that would clearly reflect on possible conclusions are in this section. Each figures and table should have brief descriptions. Figure/Image formats if using Photoshop should be:



7. Discussion: This section discusses the current study's result with previous studies and how it can affect the purpose of the study. More importantly, conclusions are drawn in this section.
8. Acknowledgments
9. References: Reference style follows the following format:

- For published journal articles:

*Author/s (Surname, First and middle Initials). Title. Journal/Publication Year; Volume No: page/s.*

Example: Gutmann JL, Primus CM, Regan JD, Hill G, Woodmansey KF, Tay FR. Biocompatibility of a mineral trioxide aggregate-based root canal sealer - ProRoot® ES (Endo Sealer). *Int J Endod Rehabil* 2015;1:3-11.

- For published online articles:

*Author/s (Surname, First and middle Initials). Title. Journal/Publication Year; Volume No: page/s; Link.*

Example: Primus CM, Gutmann JL, Yapp R, Tay FR. Physical properties of new generation tricalcium silicate dental materials. *Bioceram Dev Appl* 2014;4:76, 2014; <http://dx.doi.org/10.4172/2090-5025>.

#### A. ORIGINAL CASE REPORTS:

1. Title (same as in Section A)
2. Introduction
3. Case history
4. Materials and Methods
5. Discussion
6. Conclusion
7. Acknowledgements
8. References

## IV. Submission Procedure

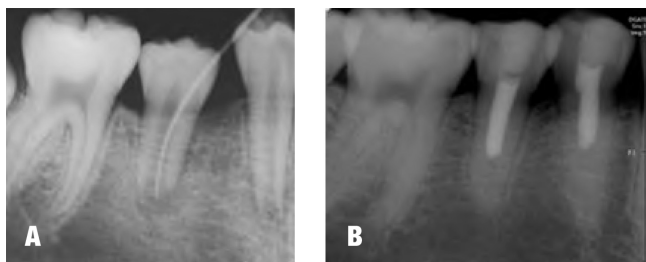
Submissions are to be emailed to [espjournal@yahoo.com](mailto:espjournal@yahoo.com). Acceptance of article will be notified to the main author through email. Unless the author has complied and has satisfied all members of *The ESP Journal* editorial board before the cut-off date for the upcoming issue, the article will be considered "pending" and will not be published on the said upcoming issue.

## Regenerative Endodontics

### What is Regenerative Endodontics?

The management of immature permanent teeth with pulpal necrosis is challenging as the root canal system is often difficult to debride and the thin dentinal walls are at an increased risk of a subsequent cervical fracture (1). This results in a restorative problem since implants are generally contraindicated in young patients with a growing craniofacial skeleton. **Regenerative endodontic therapy** provides an alternative treatment approach that builds on the principles of regenerative medicine and tissue engineering. The aim of the therapy is to successfully treat these challenging cases by regenerating functional pulpal tissue utilizing protocols referred to as **regenerative endodontic procedures (REPs)**.

Regenerative endodontic therapy has been defined as “biologically based procedures designed to replace damaged structures, including dentin and root structures, as well as cells of the pulp-dentin complex” (2). In the immature tooth with pulpal necrosis, this optimally translates to complete restoration of pulpal function and subsequent completion of root development (3). Case studies have shown that healing of apical periodontitis, continued development of the root apex and increased thickness of the root canal wall of immature teeth with pulpal necrosis can occur after REPs (Figure 1).



**Fig. 1. (A) Preoperative radiograph of tooth #29. (B) Five-year follow-up after regenerative endodontic treatment. Reprinted with permission from Jung IY, Lee SJ, Hargreaves KM. Biologically based treatment of immature permanent teeth with pulpal necrosis: a case series. J Endod 2008;34:876–87.**

Regenerative endodontics evolved out of early experiments on the role of the blood clot in endodontic therapy (4), coupled with an understanding that revascularization, or reestablishment of a vascular supply to existing pulp tissue, is essential for continuation of root development after traumatic injuries (5). Other contributing factors have been

the expansion of stem cell research, in particular the discovery of mesenchymal stem cells with the potential to differentiate into odontogenic-like cell lines (6, 7) and the potential for therapeutic applications of tissue engineering (8).

### What is Tissue Engineering?

Tissue engineering is an interdisciplinary field that integrates the principles of biology and engineering to develop biological substitutes that replace or regenerate human cells, tissue or organs in order to restore or establish normal function (9). There are three key elements for tissue engineering: **stem cells, scaffolds and growth factors**.

Dental Stem Cells	
DPSCs	Dental pulp stem cells (10)
SHEDs	Stem cells from human-exfoliated deciduous teeth (11)
PDLSCs	Periodontal ligament stem cells (12)
DFPCs	Dental follicle progenitor stem cells (13)
SCAPs	Stem cells from apical papilla (14, 15)

### Stem Cells

Stem cells are undifferentiated cells that continuously divide. There are two main types: embryonic, and adult or postnatal. Embryonic stem cells are capable of developing more than 200 cell types. In contrast, an adult stem cell can divide and create another cell like itself, and also a cell more differentiated than itself, but the capacity for differentiation into other cell types is limited. This is described as being “multipotent” and is a distinguishing feature of adult stem cells compared to the “pluripotent” or “omnipotent” properties seen in embryonic stem cells. Several types of adult stem cells have been isolated from teeth, as identified in the table above (9).

### Scaffolds

Scaffolds provide support for cell organization, proliferation, differentiation and vascularization (16). Current REPs have utilized dentin as well as the blood clot (17) or platelet-rich plasma (18) to provide scaffolds in the root canal. However, many types of biodegradable or permanent scaffolds made of natural (collagen, hyaluronic acid, chitosan and chitin) or synthetic (polylactic acid, polyglycolic acid, tricalcium phosphate, hydroxyapatite) materials are available (19, 20). Recently, peptide hydrogel nanofibers and various fibrin gels have been investigated as potential scaffolds for dental pulp tissue engineering (21).

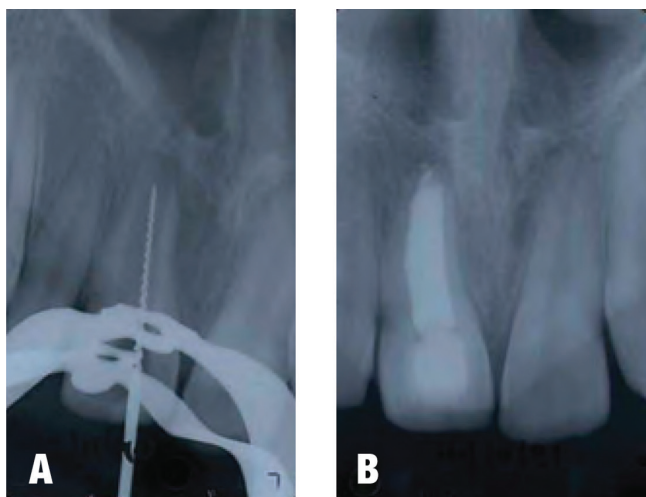
## Growth Factors

Growth factors are proteins that bind to receptors on the cell and act as signals to induce cellular proliferation and/or differentiation (2). Examples of key growth factors in pulp and dentin formation include bone morphogenetic protein (22), transforming growth factor- $\beta$  (23) and fibroblastic growth factor (24). Current REPs aim to utilize growth factors found in platelets (18) and dentin (25). Recent studies have shown that dentin contains a number of bioactive molecules that, when released, play an important role in regenerative procedures (25, 26).

## What is the Biological Basis for Regenerative Endodontic Therapy?

Historically, long-term calcium hydroxide treatment was used to induce apexification of the immature tooth with pulpal necrosis before placing an obturation material such as gutta-percha in the root canal system (27) (Figure 2). While the success rate of calcium hydroxide apexification is reported to be as high as 95%, there are several associated problems (28). These include:

1. The time required for formation of the calcified barrier (3-24 months) (27, 29)
2. Multiple appointments needed for reapplication of calcium hydroxide
3. The effect of long-term (several months or more) calcium hydroxide on the mechanical properties of dentin (30, 31)



**Fig. 2. (A) Preoperative radiographic of tooth #8 prior to multi-appointment calcium hydroxide treatment to induce apexification. (B) One-year follow-up. While the tooth is asymptomatic and functional, thin root walls put the root at increased risk of fracture.**

It has been proposed that exposure to calcium hydroxide denatures the carboxylate and phosphate groups in dentin (30). Other studies found the highest frequency of fracture occurred in teeth with the least developed roots (1).

Mineral trioxide aggregate (MTA), used as a root-end filling material, offers an alternative treatment for apexification. When placed adjacent to the periradicular tissues it induces the formation of cementum-like hard tissue and offers several advantages over calcium hydroxide apexification (32, 33). These include a reduction in treatment time and fewer patient visits, which in turn facilitate the timely restoration of the tooth. Studies on MTA apexification report

that the success rate of the treatment is as high as 94% (34). Prospective clinical trials comparing MTA apexification to calcium hydroxide apexification report that the success rate of the former is comparable to or higher than that of the latter (35, 36). The long-term ( $\geq 2$  years) success rate of MTA apexification is yet to be evaluated.

However, neither of the apexification treatments fosters further root development and immature teeth remain vulnerable to cervical root fractures. In contrast, regenerative endodontic therapy has the potential for increased root development, and thus, may confer a better long-term prognosis. In addition, successful regeneration of the pulp-dentin complex would likely result in vital tissue capable of mounting an immune response and signaling tissue damage by sensory neurons.

## What are the Considerations for Clinical Regenerative Endodontic Procedures?

Various regenerative endodontic treatment protocols have been associated with a successful clinical outcome and currently there is no single recommended protocol. Common features of cases with successful clinical outcomes after REPs (3, 37) are:

1. Young patient
2. Necrotic pulp and immature apex
3. Minimal or no instrumentation of the dentinal walls
4. Placement of an intracanal medicament
5. Creation of a blood clot or protein scaffold in canal
6. Effective coronal seal

Regenerative endodontics often involves a two- or multi-step procedure (37, 38). The first appointment is centered on proper access and disinfection of the pulp space. Upon confirming the absence of clinical signs and symptoms, the second appointment focuses on removing the antimicrobial medicament, releasing growth factors from the dentin (*e.g.*, by irrigating with ethylenediaminetetraacetic acid (EDTA)), delivering stem cells into the root canal by stimulating bleeding (39), creating a scaffold (*e.g.*, blood clot or platelet-rich plasma) (17, 18), sealing the tooth by placing a pulp space barrier (*e.g.*, MTA or resin-modified glass-ionomer) and permanent coronal restoration to prevent bacterial reinfection (40). At the second appointment, the use of local anesthetic without a vasoconstrictor may better facilitate stimulation of apical bleeding (41).

## ADA CDT Codes for Pulpal Regeneration Procedures

### First Phase of Treatment:

D3351 debridement and placement of antibacterial medication

### Interim Phase (Repeat of First Phase):

D3352 interim medication replacement

### Final Phase:

D3354 pulpal regeneration—(completion of regenerative treatment in an immature permanent tooth with a necrotic pulp); does not include final restoration

The AAE has developed treatment considerations based

on a review of case studies that is available from the AAE website at [www.aae.org/Dental\\_Professionals/Considerations\\_for\\_Regenerative\\_Procedures.aspx](http://www.aae.org/Dental_Professionals/Considerations_for_Regenerative_Procedures.aspx). These considerations should be seen as one possible source of information and, given the rapidly evolving nature of this field, clinicians should also actively review new findings elsewhere as they become available. In addition, it is important to recognize that treatment considerations have evolved based on preclinical investigations and clinical case studies and therefore provide a lower level of evidence than would be provided by controlled clinical trials. Prospective randomized clinical trials are needed to provide unbiased evaluations of different REPs and potential adverse events, as well as consensus on appropriate methods to evaluate clinical outcomes of regenerative endodontic therapies in humans where histological evaluation is not feasible.

As more evidence becomes available, modification of REPs is certain to evolve. For example, the triple antibiotic paste originally used by Banchs and Trope (17) has been shown in a recent *in vitro* study to be cytotoxic to stem cells at clinically recommended concentrations (42). As well, sodium hypochlorite and chlorhexidine can reduce the attachment of stem cells to dentin (43); in the case of NaOCl these effects have been shown to be reversed by EDTA (44).

#### Guidelines for Follow-up Evaluation

- **Tooth is asymptomatic and functional**
- **Radiographic evaluation:**
  - 6-12 months*
    - \* Resolution of periapical radiolucency
    - \* May see increased dentinal wall thickness
  - 12-24 months*
    - \* Increased dentinal wall thickness
    - \* Increased root length

Fig. 3. Guidelines for clinical and radiographic follow-up evaluation after regenerative endodontic procedures

#### What are the Outcomes of Regenerative Endodontic Procedures?

Successful clinical outcomes following revascularization procedures for immature permanent mandibular premolar teeth with pulpal necrosis and periapical infection were reported in landmark case reports by Iwahu et al (45) and Banchs and Trope (17) (Figure 4). Three important treatment factors were identified— disinfection of the root canal, placement of a matrix in the canal conducive to cellular proliferation and differentiation, and a bacterial tight seal of the access opening (46). This new treatment approach was proposed as a conservative alternative for young permanent teeth with immature roots and pulpal necrosis (17, 47).

The majority of human case studies have shown good clinical outcomes (absence of clinical signs and symptoms, radiographic evidence of resolution of periapical infections, continued root development and increased canal wall thickness) for immature permanent teeth with pulpal necrosis following REPs (37, 38, 48). Additional studies can be reviewed in the exclusive online bonus material for

this newsletter, available at [www.aae.org/colleagues](http://www.aae.org/colleagues). A recent retrospective analysis of radiographic and survival outcomes of 61 immature teeth treated with either REPs or apexification found significantly greater increases in root length and thickness following REPs in comparison with either calcium hydroxide apexification or MTA apexification (49).

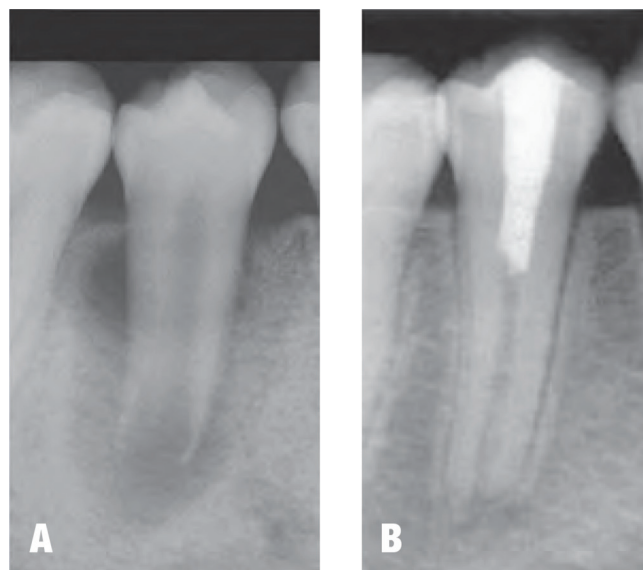


Fig. 4. (A) Preoperative radiograph of tooth #29. (B) 24-month follow-up after regenerative endodontic treatment. Reprinted with permission from Banchs F, Trope M. Revascularization of immature permanent teeth with apical periodontitis: new treatment protocol? *J Endod* 2004;30:196-200.

For obvious reasons there is limited information on the exact histological nature of the tissue in the root canal following REPs in humans. However, two recent reports describe the presence of pulp-like tissue in human teeth extracted following REPs (50, 51). In dogs, deposition of cementum- and bone-like tissues was observed after REPs (52, 53), suggesting differentiation of periodontal ligament tissue versus pulp tissue.

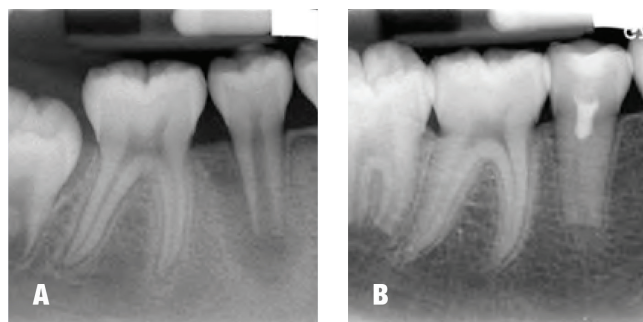


Fig. 5. (A) Preoperative radiograph of tooth #29. B. 18-month review following regenerative endodontic treatment. Courtesy of Dr. Paul Brent, Portland, Ore.

Based on case studies, the healing progression following REPs will vary depending on the initial presentation. A positive response to cold and/or electric pulp tests occurs in some cases (37). Radiographic evidence of apical healing typically precedes continuation of root development. Figure 5 shows a mandibular second premolar 18 months after REPs that remains asymptomatic and functional with complete

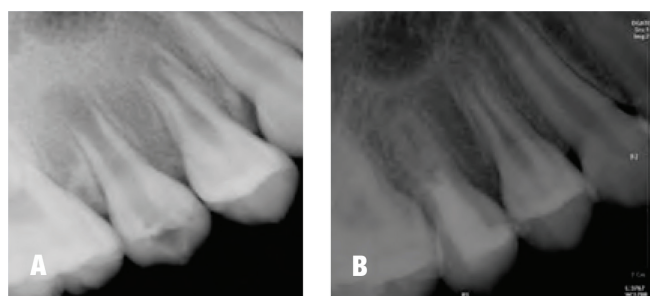
periapical healing and apical closure, but minimal increase in root length, an outcome that should be considered acceptable (37).

### What Could Regenerative Endodontics Look Like in the Future?

Current regenerative endodontic protocols rely on:

1. Irrigants to disinfect the canal and release growth factors found in dentin
2. Bleeding from the periapical area to bring cells and growth factors into the root canal
3. The blood clot and dentin walls to provide scaffolds for the generation of new tissue (17, 25, 54) (Figure 6)

It is clear that the many possible clinical variables do not give the clinician control of the stem cell/growth factors/scaffold composition. In the future, the challenge of generating tissues that mimic the original pulp and dentin-like structure might be more effectively addressed by using tissue engineering approaches under more controlled clinical conditions (54, 55). Such approaches might rely more on therapies that utilize autologous stem cells combined with customized scaffolds and delivery of appropriate growth factors at the right time and in the right sequence. Further translational research is needed to learn about these processes and, importantly, ensure that new protocols are clinically practical (56).



**Fig. 6. (A) Preoperative radiograph of tooth #4. (B) 5-year follow-up after regenerative endodontic treatment. Reprinted with permission from Jung IY, Lee SJ, Hargreaves KM. Biologically based treatment of immature permanent teeth with pulpal necrosis: a case series. J Endod 2008;34:876–87.**

### REFERENCES

1. Cvek M. Prognosis of luxated non-vital maxillary incisors treated with calcium hydroxide and filled with gutta-percha. A retrospective clinical study. *Endod Dent Traumatol* 1992;8:45-55.
2. Murray PE, Garcia-Godoy F, Hargreaves KM. Regenerative endodontics: a review of current status and a call for action. *J Endod* 2007;33:377-90.
3. Hargreaves KM, Giesler T, Henry M, et al. Regeneration potential of the young permanent tooth: what does the future hold? *J Endod* 2008;34:S51-6.
4. Nygaard-Östby B. The role of the blood clot in endodontic therapy. An experimental histologic study. *Acta Odontol Scand* 1961;19:324-53.
5. Andreasen JO, Andreasen FM. Textbook and color atlas of traumatic injuries to the teeth. 3rd ed. Munksgaard, St Louis, MO; 1994.
6. Caplan AI. Mesenchymal stem cells. *J Orthop Res* 1991;9:641-50.
7. Huang GT, Gronthos S, Shi S. Mesenchymal stem cells derived from dental tissues vs. those from other sources: their biology and role in regenerative medicine. *J Dent Res* 2009;88:792-806.
8. Langer R, Vacanti JP. Tissue engineering. *Science* 1993;260:920-6.
9. Sedgley CM, Botero TM. Dental stem cells and their sources. *Dent Clin North Am* 2012;56:549-61.
10. Gronthos S, Mankani M, Brahimi J, et al. Postnatal human dental pulp stem cells (DPSCs) in vitro and in vivo. *Proc Natl Acad Sci USA* 2000;97:13625-30.

It is evident that recent rapid advances have opened the door to exciting new opportunities in the quest for healing immature teeth with pulpal necrosis. Extension of these advances to the treatment of mature teeth with pulpal necrosis would provide significant therapeutic benefits by enabling retention of the natural dentition in a larger patient pool. Recent reports describing the presence of mesenchymal stem/progenitor cells with regenerative capabilities in human inflamed pulps (57) and inflamed periapical tissue (58) present intriguing possibilities yet to be explored for the treatment of the mature tooth with pulpal necrosis and apical periodontitis. Clearly, while current protocols have undergone rapid evolution to improve outcomes, it is likely that future REPs will differ from current practice and have the potential to provide benefits for a larger proportion of the population.

### Summary

Regenerative endodontics is one of the most exciting developments in dentistry today and endodontists are at the forefront of this cutting-edge research. Endodontists' knowledge in the fields of pulp biology, dental trauma and tissue engineering can be applied to deliver biologically based regenerative endodontic treatment of necrotic immature permanent teeth resulting in continued root development, increased thickness in the dentinal walls and apical closure. These developments in regeneration of a functional pulp-dentin complex have a promising impact on efforts to retain the natural dentition, the ultimate goal of endodontic treatment.



11. Miura M, Gronthos S, Zhao M, et al. SHED: stem cells from human exfoliated deciduous teeth. *Proc Natl Acad Sci USA* 2003;100:5807-12.
12. Seo BM, Miura M, Sonoyama W, et al. Recovery of stem cells from cryopreserved periodontal ligament. *J Dent Res* 2005;84:907-12.
13. Morsczeck C, Gotz W, Schierholz J, et al. Isolation of precursor cells (PCs) from human dental follicle of wisdom teeth. *Matrix Biol* 2005;24:155-65.
14. Huang GT, Sonoyama W, Liu Y, et al. The hidden treasure in apical papilla: the potential role in pulp/dentin regeneration and bioroot engineering. *J Endod* 2008;34:645-51.
15. Sonoyama W, Liu Y, Yamaza T, et al. Characterization of the apical papilla and its residing stem cells from human immature permanent teeth: a pilot study. *J Endod* 2008;34:166-71.
16. Bohl KS, Shon J, Rutherford B, et al. Role of synthetic extracellular matrix in development of engineered dental pulp. *J Biomater Sci Polym Ed* 1998;9:749-64.
17. Banchs F, Trope M. Revascularization of immature permanent teeth with apical periodontitis: new treatment protocol? *J Endod* 2004;30:196-200.
18. Torabinejad M, Turman M. Revitalization of tooth with necrotic pulp and open apex by using platelet-rich plasma: a case report. *J Endod* 2011;37:265-8.
19. Gotlieb EL, Murray PE, Namerow KN, et al. An ultrastructural investigation of tissue-engineered pulp constructs implanted within endodontically treated teeth. *J Am Dent Assoc* 2008;139:457-65.
20. Chandrhasa S, Murray PE, Namerow KN. Proliferation of mature ex vivo human dental pulp using tissue engineering scaffolds. *J Endod* 2011;37:1236-9.
21. Galler KM, Hartgerink JD, Cavender AC, et al. A customized self-assembling peptide hydrogel for dental pulp tissue engineering. *Tissue Eng Part A* 2012;18:176-84.
22. Nakashima M. Bone morphogenetic proteins in dentin regeneration for potential use in endodontic therapy. *Cytokine Growth Factor Rev* 2005;16:369-76.
23. Chan CP, Lan WH, Chang MC, et al. Effects of TGF-betas on the growth, collagen synthesis and collagen lattice contraction of human dental pulp fibroblasts in vitro. *Arch Oral Biol* 2005;50:469-79.
24. Ishimatsu H, Kitamura C, Morotomi T, et al. Formation of dentinal bridge on surface of regenerated dental pulp in dentin defects by controlled release of fibroblast growth factor-2 from gelatin hydrogels. *J Endod* 2009;35:858-65.
25. Smith AJ, Scheven BA, Takahashi Y, et al. Dentine as a bioactive extracellular matrix. *Arch Oral Biol* 2012;57:109-21.
26. Sun HH, Jin T, Yu Q, et al. Biological approaches toward dental pulp regeneration by tissue engineering. *J Tissue Eng Regen Med* 2011;5:e1-16.
27. Frank AL. Therapy for the divergent pulpless tooth by continued apical formation. *J Am Dent Assoc* 1966;72:87-93.
28. Kerkis I, Kerkis A, Dozortsev D, et al. Isolation and characterization of a population of immature dental pulp stem cells expressing OCT-4 and other embryonic stem cell markers. *Cells Tissues Organs* 2006;184:105-16.
29. Webber RT. Apexogenesis versus apexification. *Dent Clin North Am* 1984;28:669-97.
30. Andreasen JO, Farik B, Munksgaard EC. Long-term calcium hydroxide as a root canal dressing may increase risk of root fracture. *Dent Traumatol* 2002;18:134-7.
31. Rosenberg B, Murray PE, Namerow K. The effect of calcium hydroxide root filling on dentin fracture strength. *Dent Traumatol* 2007;23:26-9.
32. Torabinejad M, Hong CU, Lee SJ, et al. Investigation of mineral trioxide aggregate for root-end filling in dogs. *J Endod* 1995;21:603-8.
33. Shabahang S, Torabinejad M, Boyne PP, et al. A comparative study of root-end induction using osteogenic protein-1, calcium hydroxide, and mineral trioxide aggregate in dogs. *J Endod* 1999;25:1-5.
34. Sarris S, Tahmassebi JF, Duggal MS, et al. A clinical evaluation of mineral trioxide aggregate for root-end closure of non-vital immature permanent incisors in children-a pilot study. *Dent Traumatol* 2008;24:79-85.
35. El-Meligy OA, Avery DR. Comparison of apexification with mineral trioxide aggregate and calcium hydroxide. *Pediatr Dent* 2006;28:248-53.
36. Pradhan DP, Chawla HS, Gauba K, et al. Comparative evaluation of endodontic management of teeth with unformed apices with mineral trioxide aggregate and calcium hydroxide. *J Dent Child (Chic)* 2006;73:79-85.
37. Law A. Considerations for regeneration procedures. *J Endod* 2013;39(3 Suppl):S44-56.
38. Geisler TM. Clinical considerations for regenerative endodontic procedures. *Dent Clin North Am* 2012;56:603-26.
39. Lovelace TW, Henry MA, Hargreaves KM, et al. Evaluation of the delivery of mesenchymal stem cells into the root canal space of necrotic immature teeth after clinical regenerative endodontic procedure. *J Endod* 2011;37:133-8.
40. Jung IY, Lee SJ, Hargreaves KM. Biologically based treatment of immature permanent teeth with pulpal necrosis: a case series. *J Endod* 2008;34:876-87.
41. Petrino JA, Boda KK, Shambarger S, et al. Challenges in regenerative endodontics: a case series. *J Endod* 2010;36:536-41.
42. Ruparel NB, Teixeira FB, Ferraz CC, et al. Direct effect of intracanal medicaments on survival of stem cells of the apical papilla. *J Endod* 2012;38:1372-5.
43. Ring KC, Murray PE, Namerow KN, et al. The comparison of the effect of endodontic irrigation on cell adherence to root canal dentin. *J Endod* 2008;34:1474-9.
44. Galler KM, D'Souza RN, Federlin M, et al. Dentin conditioning codetermines cell fate in regenerative endodontics. *J Endod* 2011;37:1536-41.
45. Iwaya SI, Ikawa M, Kubota M. Revascularization of an immature permanent tooth with apical periodontitis and sinus tract.

---

Dent Traumatol 2001;17:185- 7.

46. Windley III W, Teixeira F, Levin L, et al. Disinfection of immature teeth with a triple antibiotic paste. *J Endod* 2005;31:439-43.
47. Trope M. Treatment of the immature tooth with a non-vital pulp and apical periodontitis. *Dent Clin North Am* 2010;54:313-24.
48. Hargreaves KM, Diogenes A, Teixeira F. Treatment options: biological basis of regenerative endodontic procedures. *J Endod* 2013;39(3 Suppl):S30-43.
49. Jeeruphan T, Jantarat J, Yanpiset K, et al. Mahidol study 1: comparison of radiographic and survival outcomes of immature teeth treated with either regenerative endodontic or apexification methods: a retrospective study. *J Endod* 2012;38:1330-6.
50. Torabinejad M, Faras H. A clinical and histological report of a tooth with an open apex treated with regenerative endodontics using platelet-rich plasma. *J Endod* 2012;38:864-8.
51. Shimizu E, Jong G, Partridge N, et al. Histologic observation of a human immature permanent tooth with irreversible pulpitis after revascularization/ regeneration procedure. *J Endod* 2012;38:1293-7.
52. Thibodeau B, Teixeira F, Yamauchi M, et al. Pulp revascularization of immature dog teeth with apical periodontitis. *J Endod* 2007;33:680-9.
53. Wang X, Thibodeau B, Trope M, et al. Histologic characterization of regenerated tissues in canal space after the revitalization/ revascularization procedure of immature dog teeth with apical periodontitis. *J Endod* 2010;36:56-63.
54. Galler KM, D'Souza RN. Tissue engineering approaches for regenerative dentistry. *Regen Med* 2011;6:111-24.
55. Smith AJ, Lesot H. Induction and regulation of crown dentinogenesis: embryonic events as a template for dental tissue repair? *Crit Rev Oral Biol Med* 2001;12:425-37.
56. Goodis HE, Kinaia BM, Kinaia AM, et al. Regenerative endodontics and tissue engineering: what the future holds? *Dent Clin North Am* 2012;56:677-89.
57. Alongi DJ, Yamaza T, Song Y, et al. Stem/progenitor cells from inflamed human dental pulp retain tissue regeneration potential. *Regen Med* 2010;5:617- 31.
58. Liao J, Al Shahrani M, Al-Habib M, et al. Cells isolated from inflamed periapical tissue express mesenchymal stem cell markers and are highly osteogenic. *J Endod* 2011;37:1217-24.

The AAE wishes to thank the members of its Regenerative Endodontics Committee for authoring this issue of the newsletter: Drs. Christine M. Sedgley, Pavel Cherkas, Sami M.A. Chogle, Todd M. Geisler, Kenneth M. Hargreaves, Avina K. Paranjpe and Valerie Tom-Kun Yamagishi. Thanks also to the following article reviewers: Drs. Steven J. Katz, James C. Kulild, Robert S. Roda, James F. Wolcott and Susan L. Wolcott.

## Management of Endodontic Emergencies: Pulpotomy Versus Pulpectomy

Recent studies report a 60-82% incidence of endodontic emergencies among all dental emergencies (1, 2). Within this group, 20-42% of patients seek care for teeth with symptomatic irreversible pulpitis (SIP) (1-3). Additionally, about 60% of SIP patients also complain of symptomatic apical periodontitis (SAP) (3). While pain due to a severely inflamed pulp is characterized by dull, throbbing and lingering pain sensations, it can be spontaneous or in response to an external stimulus, such as hot, cold or chewing. This makes SIP the bulk of the emergency cases seen in dental clinics.

The goal of management of endodontic emergencies is to quickly and effectively manage pain and infections thereby also minimizing the development of persistent pain and the formation of periapical pathology. Pharmacological management such as intramuscular or infiltration injection of ketorolac trimethamine (injectable NSAID) can significantly attenuate pain in patients with moderate to severe pulpal pain over a three-hour tested time (4, 5) or oral administration of ibuprofen sodium dihydrate over a one-hour time period (6). These treatments have yet to be evaluated over days or weeks after drug administration but before completion of endodontic therapy. Therefore, until research becomes available substantiating the long-term effectiveness of pharmacological management, procedural interventions remain the gold standard.

On the other hand, procedural interventions such as

pulpotomies and pulpectomies have been the first line of emergency treatments with pulpectomy being the preferred choice of treatment (Figure 1). As seen in Figure 1, a survey of Diplomates of the American Board of Endodontics demonstrated that more endodontists were inclined towards pulp extirpation/pulpectomy compared to pulpotomy-only procedures for both vital and necrotic cases (7-9). Moreover, more than 50% of endodontists preferred complete instrumentation compared to pulpectomy-only procedures, especially in necrotic cases. Insufficient time was the primary reason for performing either pulpotomies or pulpectomies. However, this trend changed by a cumulative 27% increase in preference towards complete instrumentation over a 10-year period (Figure 1-B) (9). This shift in preference is likely explained by the increase in the literature on the effect of complete instrumentation and placement of an intracanal medicament on the reduction of bacterial toxins and cytokines that directly activate and sensitize nociceptors (10-13). Additionally, the advent of contemporary tools such as the electronic apex locator (EAL), surgical operating microscope (SOM), ultrasonic instruments and cone beam computed tomography (CBCT) have almost entirely eliminated the lack of time as a factor for selecting pulpotomy and pulpectomy without complete instrumentation. Of course, many emergency cases with pulpalgia and SAP also can be completed in one visit. However, this issue of Colleagues will focus and present scenarios related to endodontic pulpotomy and pulpectomy procedures where appropriate.

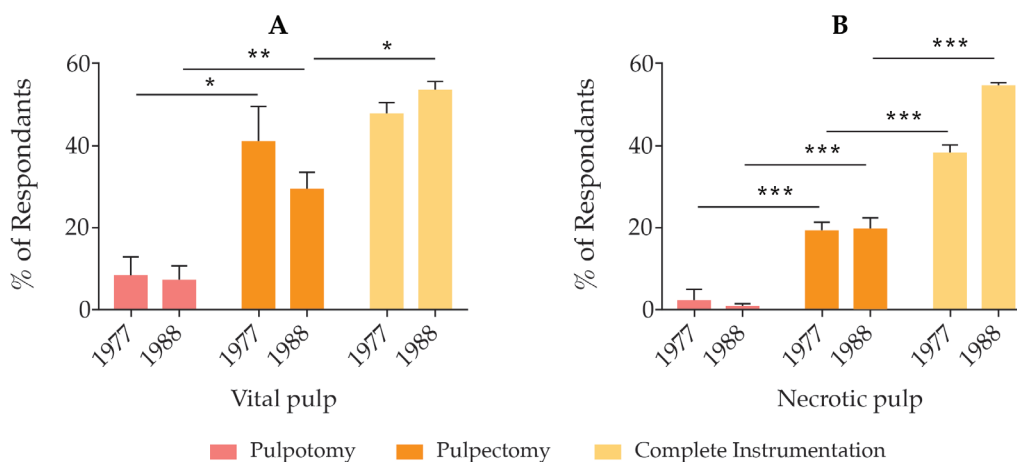
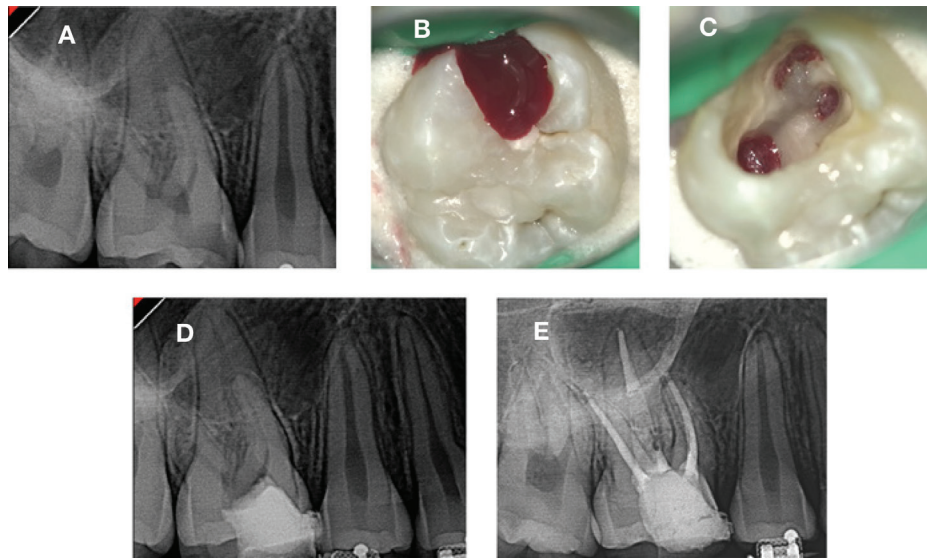


Fig. 1. Graphical representation of survey of Diplomates of the ABE regarding endodontic emergency procedures. Adapted from Dorn et al.,1977a, Dorn et al.,1977b and Gatewood et al.,1990 (7-9).



**Fig. 2. Case #1: Emergency pulpotomy of #3. Courtesy Dr. Saeed Bayat, Department of Endodontics, UTHSCSA.**

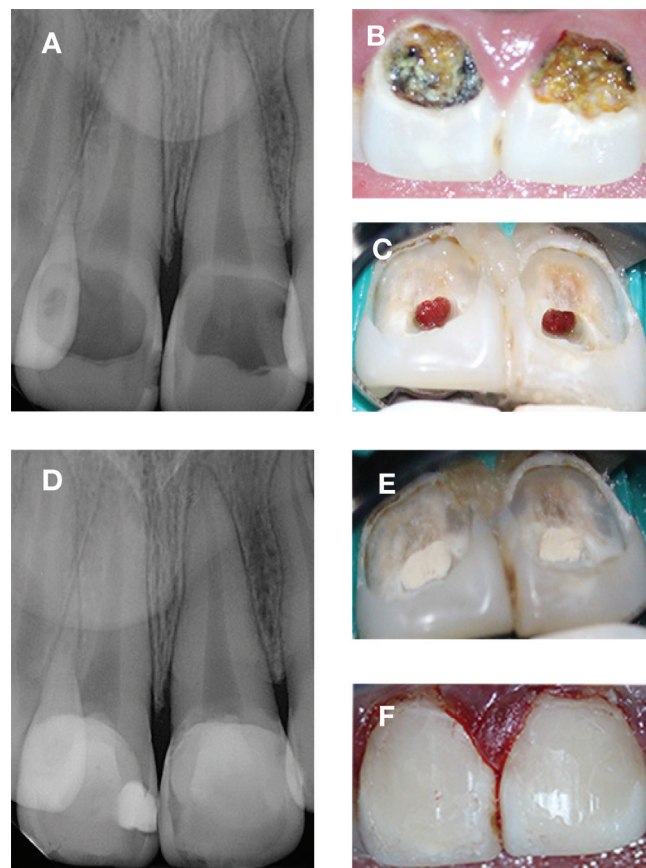
Pulpotomy and pulpectomy differ essentially in that pulpotomy protocols are limited to the removal of inflamed tissue restricted to the pulp chamber while pulpectomy protocols require extirpation of the inflamed tissue in the root canal system. Although pulpectomy is a terminology best suited for vital pulps, it also is used in reference to the removal of necrotic tissues from root canals. Generally speaking, both procedures have greater than a 90% success rate in reducing postoperative pain from moderate to severe to mild to no pain (5, 14-18). Continued research on these protocols has led to new advances and highly predictable outcomes.

### Pulpotomy

Emergency cases with a diagnosis of SIP due to caries, large restorations, cracked tooth syndrome or trauma are potential candidates for pulpotomies. The primary reason for electing to do a pulpotomy over complete instrumentation is the lack of sufficient time to clean and shape canal systems. Additionally, partial pulpectomy of severely inflamed teeth has been strongly discouraged over pulpotomy due to an arbitrary method of axotomizing sensory nerves due to upregulation of genes such as nerve growth factor responsible for peripheral nerve sprouting and therefore greater postoperative pain (14, 19).

Prior studies determining pulpotomy protocols suggest that an effective procedure can be accomplished with adequate removal of the inflamed pulp tissue, preferably at the level of the canal orifice/s followed by a well-suited coronal seal. Prevention of bacterial penetration during the intermediate time until definitive endodontic therapy can be initiated is the primary purpose of an adequate coronal seal. To this end, many clinicians prefer placement of an antibacterial chamber dressing following a pulpotomy. It should be noted that there appears to be no difference between various antibacterial chamber dressings compared to a dry cotton pellet with regards to attenuation of pain (16). However, the length of time between an emergency pulpotomy and definitive endodontic treatment does appear to be a critical factor for pain relief. A study by McDougal and colleagues suggests that definitive endodontic treatment must be initiated within

six months of an emergency pulpotomy to avoid another painful episode (20). Case #1 is an example of a 14-year-old patient with a history of spontaneous pain of two-month duration and tenderness to biting on tooth #3 who received an emergency pulpotomy procedure. Pre-operative pain was reported as three on a 0-5 scale. Clinical and radiographic examination revealed a diagnosis of SIP with SAP. Patient-related factors permitted only a quick pulpotomy at the first visit, which involved maxillary infiltration, rubber dam isolation, removal of pulp chamber tissue, hemostasis with



**Fig. 3. Case #2: Emergency pulpotomy of #8 and 9. Courtesy Dr. Koyo Takimoto, Department of Endodontics, UTHSCSA.**

8.25% sodium hypochlorite, placement of cotton-soaked eugenol over orifices (Figure 2-C) and coronal seal with Intermediate Restorative Material™ (Figure 2-D). The patient was asymptomatic at 24 hours and at one-week post treatment. At one week, definitive endodontic treatment was initiated and completed. Due to loss of the mesial marginal ridge, a fiber post was cemented in the palatal canal and tooth was restored with composite resin (Figure 2-E).

With our increasing understanding of the biology and pathogenesis of pulpitis and the evolution of various biocompatible materials, emergency pulpotomy procedures can now also be applied as definitive treatment procedures (See Figures 3 and 4). Case #2 represents a unique case of a “restorative emergency.” A 16-year-old patient was referred for emergency treatment of #8 and 9 due to severe caries-induced weakening of the facial surfaces (Figures 3-A and 3-B). Diagnosis of reversible pulpitis and normal periradicular tissues was made. Following local anesthesia, rubber dam isolation and caries excavation, the inflamed pulp was removed. Hemostasis was achievable following this step (Figure 3-C). Due to the patient’s age and the open apices, a decision to perform a pulpotomy as definitive treatment was made. Biodentine®, a bioactive dentin substitute, was placed over the amputated pulps (Figure 3-D) followed by Fuji IX glass ionomer. Access cavities were restored to contour with Z-100 composite restorations (Figures 3-E and 3-F). Case #3 is an example of a pulpotomy performed in a trauma case. A 10-year-old female patient reported for tooth #8 four days after a bicycle accident and emergency room treatment of her upper lip (Figure 4-A and 4-B). Clinical presentation revealed a complicated crown fracture (enamel and dentin fracture with pulp exposure) with no treatment initiated. A diagnosis of reversible pulpitis with SAP was made. Following rubber dam isolation, a partial pulpotomy to eliminate the inflamed pulp was done (Figure 4-C) and Biodentine® was placed immediately (Figure 4-C). The tooth was restored with Fuji IX and a Vitalescence™ composite restoration (Figure 4-D). A one-year follow up documented a vital #8, no discoloration and a dense dentin bridge below the restorative material. This is one of two reports of Biodentine-induced osteo-induction in a patient (21).

## Pulpectomy

Emergency cases with vital and necrotic pulps can benefit

from pulpectomy procedures. As mentioned above, although the success of pulp extirpation is high, partial pulpectomy can be problematic in certain scenarios and should be avoided due to reasons such as 1) sensory nerve sprouting from “random” peripheral axotomy; 2) residual inflamed tissue as a source of pain; and 3) residual necrotic tissue that precludes adequate chemo-mechanical debridement. Therefore, several protocol changes have been seen over the years; complete instrumentation with placement of an intracanal medicament is now the preferred choice among most endodontists (22). As stated earlier, technological advancements such as the EAL make it seamless to determine the ideal working length (<2mm of apex) (23) for full instrumentation. Moreover, a dramatic shift in the type of intracanal medicament used is seen. A significantly greater number of endodontists use calcium hydroxide (Ca(OH)<sub>2</sub>) as an interappointment medicament (9, 22). This is not surprising owing to its bactericidal and detoxification effect (11, 24). Importantly, this also reflects the concept that leaving the tooth open for drainage is no longer considered beneficial (7, 8, 22, 25). The common theme is microbial control.

An emergency appointment also is a perfect opportunity to evaluate the overall survivability of the offending tooth. For example, as seen in Case #4 (Figure 5-A), the patient reported a five out of five pain scale and was diagnosed as a typical case of SIP with SAP. Upon access, a mesio-distal (MD) macroscopic fracture was observed. Further visualization with an SOM and methylene blue staining revealed microscopic extension of the fracture line into the DB canal orifice. The tooth was deemed non-restorable; partial pulpectomy was performed to avoid enlarging the root fractures and an immediate referral to the oral surgery clinic was made. Several similar cases are shown in Figure 5-B, -C, and -D. Several diagnostic tools such as the Tooth Sleuth®, transillumination and visualization of large fractures with loupes are available to dentists; however, deep fracture lines extending to the pulpal floor and into canal systems are often missed with routine diagnostic tools. These cases showcase one of the many valuable advantages of an SOM as well as CBCT (Figure 5-D).

Advantages of small volume CBCT is well documented (26) and having access to one can elevate the quality of care provided to patients. Case #5 (Figure 6) illustrates this very

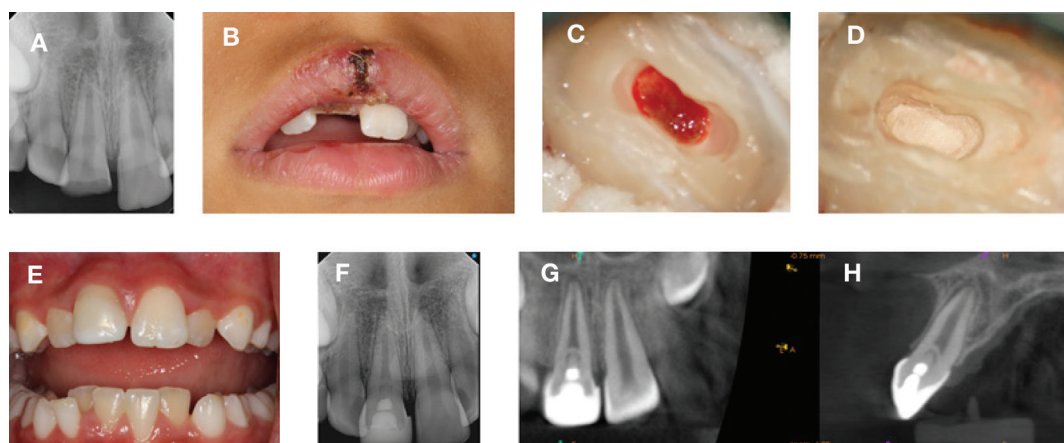
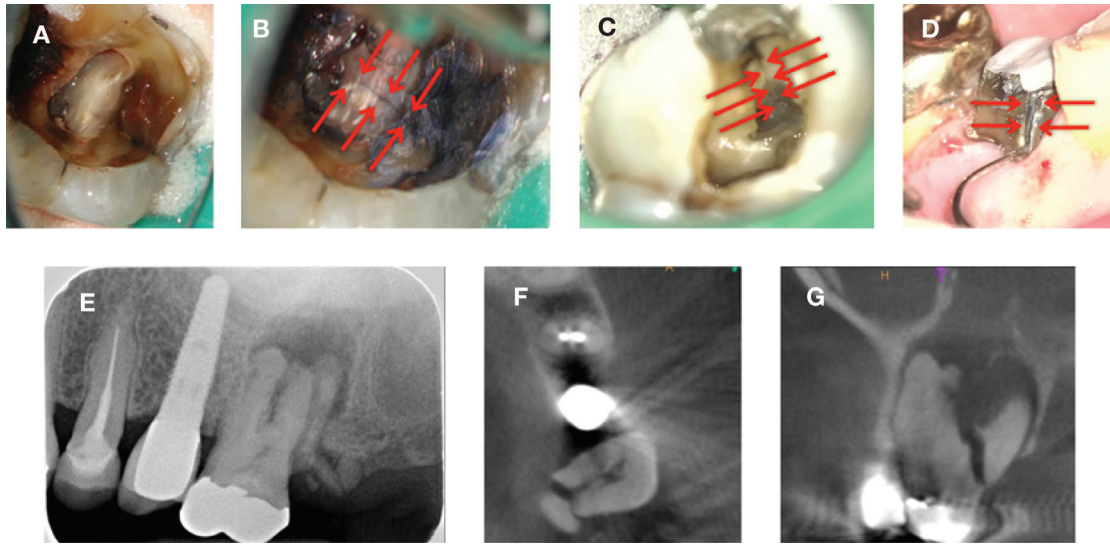


Fig. 4. Case #3: Emergency pulpotomy for trauma on #8. Courtesy Dr. Anibal Diogenes, Department of Endodontics, UTHSCSA.

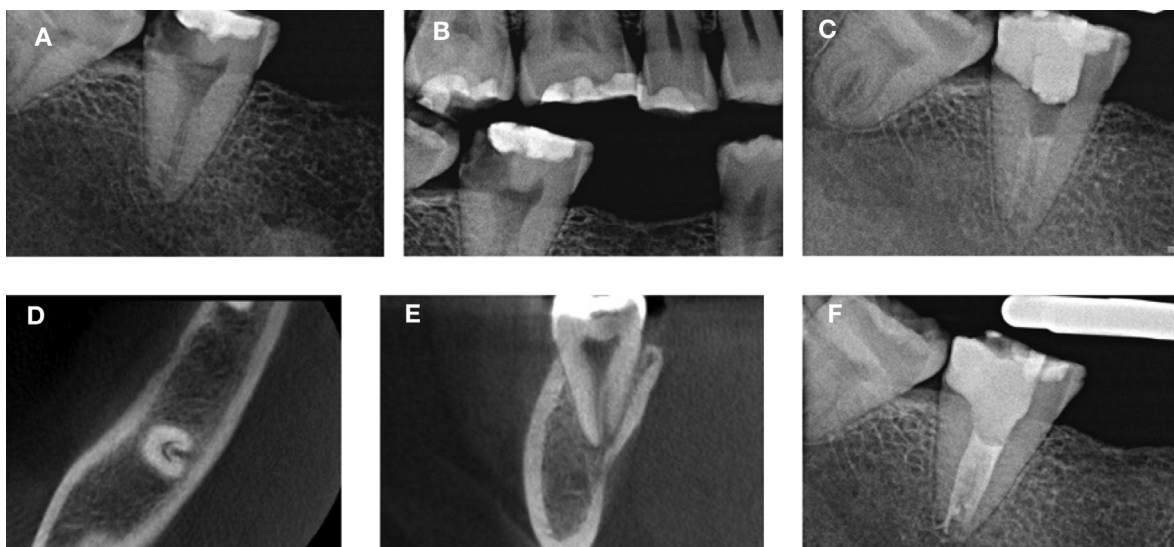


**Fig. 5. Case #4: Emergency pulpectomy with visualization of MD crack on #14. (A). Visualization of vertical fracture extending into MB orifice of #3 (B) and subgingival fracture extending on #30 (C) using SOM. Demonstration of split palatal root of #14 using CBCT (D). Courtesy several endodontists, Department of Endodontics, UTHSCSA.**

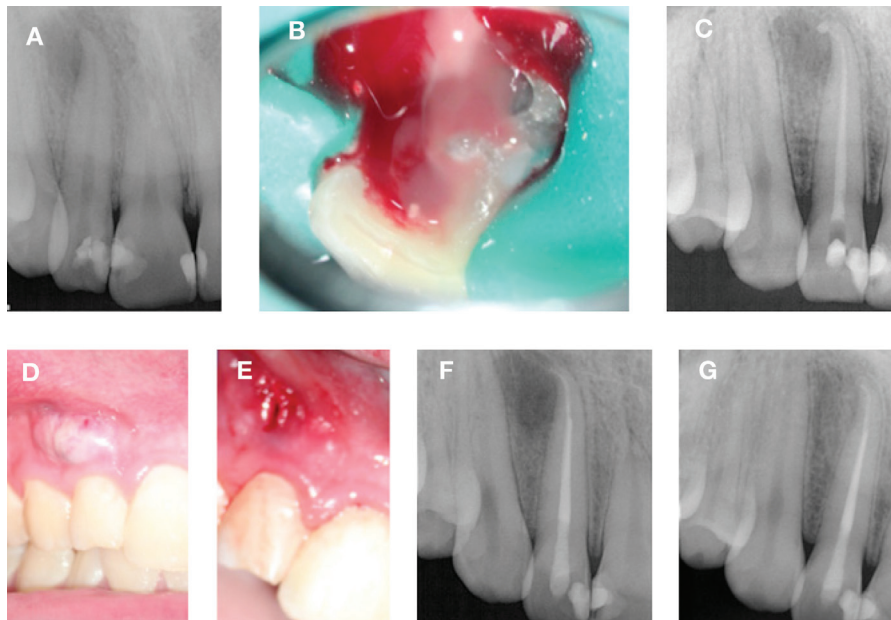
advantage of CBCT imaging. The patient reported a four out of five spontaneous pain with a diagnosis of SIP with SAP. The pre-operative radiograph revealed an unusual second molar anatomy with several canal ramifications, indistinct furca and an indistinguishable apical extent (Figure 6-A). These features are consistent with a C-shaped canal anatomy. Considering that the incidence of this anatomy in second molars ranges from 5-8% (27, 28), a CBCT scan confirmed a “continuous C-shaped” anatomy with  $\approx 1\text{mm}$  thickness of the lingual dentin wall (Figure 6-D and 6-E). The complex anatomy of such a tooth poses additional challenges for the clinician with these emergency cases—in this case, obtaining successful anesthesia (29), locating all the anatomy for adequate instrumentation as well as careful decision making with respect to prevention of iatrogenic complications such as strip perforations. To avoid further distress to the patient, supplemental anesthesia was administered using 3% mepivacaine with an intra-osseous injection technique. Upon entry into the chamber, intrapulpal anesthesia was

administered. Additionally, a well-informed decision could be made to employ advanced tools such as ultrasonic instruments as well as to instrument the lingual aspect of the canal conservatively. The canal system was then medicated with Ca(OH) (Figure 2 6-C) and the patient was completely asymptomatic after the appointment. The case was completed with no complications at the second visit (Figure 6-F).

Case #6 is an example of a severely infected tooth #7 with pre-operative pain of four out of five. A partial pulpectomy was performed two weeks prior. Clinical examination revealed extraoral and intraoral (I/O) localized, fluctuant swelling obscuring the labial vestibule near #7 (Figure 7-D). The tooth was diagnosed as previously initiated therapy with acute apical abscess. Anesthesia was a challenge in this patient due to soft tissue involvement. Therefore, an infra-orbital nerve block injection was performed. Upon access, a large amount of purulent drainage was observed (Figure 7-B). The tooth was allowed to drain for 20 minutes with continuous irrigation



**Fig. 6. Case #5: Emergency pulpectomy with complete instrumentation of #18. Courtesy Dr. David Martin, Department of Endodontics, UTHSCSA.**



**Fig. 7. Case #6: Emergency pulpectomy with complete instrumentation and Incision and Drainage of #7. Courtesy Dr. Obadah Austah, Department of Endodontics, UTHSCSA.**

and suction before observing cessation of the drainage. The tooth had a working length of 27mm, a possible reason for incomplete instrumentation at the previous emergency appointment. Complete instrumentation was performed followed by placement of Ca(OH)<sub>2</sub> and an intact coronal seal (Figure 7-C). Additionally, the I/O swelling also was drained with an incision and drainage (I&D) procedure (Figure 7-E). This step provided significant pain relief for the patient by reducing any pressure-induced mechanical allodynia in the periapical tissues. The patient was prescribed a seven-day course of penicillin VK 500mg and treatment was completed at the second visit with no persisting soft tissue abnormality or purulence within the canal system (Figure 7-F). A two-year recall revealed completely healed periapical tissues with no signs and symptoms of pathology (Figure 7-F and 7-G).

### Adjunctive Therapies

Several adjuncts to emergency pulpotomy and pulpectomy procedures are available and must be considered.

1. Occlusal adjustment: excellent work by Rosenberg and colleagues demonstrated that occlusal reduction significantly attenuated pain in patients with vital pulps, periradicular symptoms and pre-operative pain, 48 hours post- instrumentation (30).
2. Postoperative analgesics: recent systematic reviews and meta-analysis demonstrate that ibuprofen 600mg or ibuprofen 600mg with acetaminophen (APAP) 1000mg is most effective in attenuating postoperative endodontic pain (31, 32) in patients without contraindication. Moreover, a newer ibuprofen formulation, ibuprofen sodium dihydrate (Advil Sodium<sup>TM</sup>, Pfizer) at 512mg dose has been shown to have a faster onset of action than ibuprofen acid producing a greater reduction in spontaneous pain and mechanical allodynia (6). Although no endodontic treatment was provided in this study, a quicker onset of action of ibuprofen sodium dihydrate will likely benefit patients with post- endodontic pain. All of the patients in the above examples described were given 600mg ibuprofen plus 325mg APAP.

3. I&D: this adjunctive therapy is indicated for localized, firm or fluctuant soft tissue I/O swelling. Release of fluid pressure, reduction in microbial and inflammatory mediators and prevention of spread of infection to deeper fascial tissues are reasons for employing I&D.
4. Postoperative antibiotics: it is imperative that the clinician also observe for any systemic involvement in all patients. Cases of acute apical abscess with intra- or extraoral swelling, lymphadenopathy and/or fever are critical signs that must not be missed. These also are cues that infection from the pulp and periradicular tissues have spread to deeper and potentially dangerous regions of the body, which must be arrested immediately. Several antibiotics are available to the clinician; bactericidal/ bacteriostatic properties of various antibiotics to endodontic pathogens have been tested and demonstrate the following efficacy (33):
  - a. penicillin V – 85%
  - b. amoxicillin – 91%
  - c. amoxicillin +calvulanic acid– 100%
  - d. metronidazole – 45%
  - e. penicillin+metronidazole – 93%
  - f. amoxicillin+metronidazole – 99%
  - g. clindamycin – 96%

These data strongly suggest the use of a broader-spectrum antibiotic such as Augmentin or amoxicillin with metronidazole for a polymicrobial endodontic infection. There is no evidence that antibiotics attenuate pain and therefore over-prescription of antibiotics in the absence of systemic involvement must be avoided to prevent antimicrobial resistance in patients.

### Summary

Clinical manifestation of endodontic pain is an outcome of a series of complex cellular and molecular pathways that ultimately lead to activation and/or sensitization of peripheral nociceptors (34, 35). Bacterial components (e.g., lipopolysaccharide (LPS), lipotechoic acid (LTA), sodium

butyrate) in conjunction with cells of the pulp-dentin complex (e.g., odontoblasts, fibroblasts, dendritic cells) elicit a robust host-mediated inflammatory response. This burst of cellular activity with the release of pro-nociceptive mediators such as metabolites of arachidonic and linoleic acid, bradykinin, reactive oxygen species and cytokines significantly lower sensory neuron thresholds thereby causing a state of “nociceptor sensitization.” This state manifests itself as spontaneous and/or evoked pain that lingers. When inflammatory mediators egress into the periradicular tissues, mechanical allodynia ensues. Since pain relief with analgesics is short lasting, procedures such as pulpotomy and pulpectomy are required for definitive treatment.

The primary goal of emergency procedures is to provide significant pain relief for a sufficient duration until definitive treatment can be delivered. However, clinicians must also

achieve the following goals: 1) deliver care that will prevent the development of persistent pain and periapical pathosis thereby increasing the success rate of endodontic treatment; 2) take all measures to prevent systemic involvement; and 3) utilize this time to determine the overall survivability of the tooth in question.

Taken together, our mission as endodontists should be to constantly learn, adapt and elevate the level of care we deliver to our patients. Effective emergency care can often save the natural tooth and provide decades of service to our patients. Consultation between general practitioners and endodontists is an opportunity to provide the most appropriate care at the most appropriate time. Endodontists are dental emergency specialists that can utilize all the available tools to manage challenging emergency situations and are routinely available to their general practitioner referrals.

## REFERENCES

1. Estrela C, Guedes OA, Silva JA, Leles CR, Estrela CR, Pecora JD. Diagnostic and clinical factors associated with pulpal and periapical pain. *Braz Dent J* 2011;22:306-11.
2. Rechenberg DK, Held U, Burgstaller JM, Bosch G, Attin T. Pain levels and typical symptoms of acute endodontic infections: a prospective, observational study. *BMC Oral Health* 2016;16:61.
3. Owatz CB, Khan AA, Schindler WG, Schwartz SA, Keiser K, Hargreaves KM. The incidence of mechanical allodynia in patients with irreversible pulpitis. *J Endod* 2007;33:552-6.
4. Curtis P, Jr., Gartman LA, Green DB. Utilization of ketorolac tromethamine for control of severe odontogenic pain. *J Endod* 1994;20:457-9.
5. Penniston SG, Hargreaves KM. Evaluation of periapical injection of Ketorolac for management of endodontic pain. *J Endod* 1996;22:55-9.
6. Taggar T, Wu D, Khan AA. A Randomized Clinical Trial Comparing 2 Ibuprofen Formulations in Patients with Acute Odontogenic Pain. *J Endod* 2017;43:674-8.
7. Dorn SO, Moodnik RM, Feldman MJ, Borden BG. Treatment of the endodontic emergency: a report based on a questionnaire-part II. *J Endod* 1977;3:153-6.
8. Dorn SO, Moodnik RM, Feldman MJ, Borden BG. Treatment of the endodontic emergency: a report based on a questionnaire-part I. *J Endod* 1977;3:94-100.
9. Gatewood RS, Himel VT, Dorn SO. Treatment of the endodontic emergency: a decade later. *J Endod* 1990;16:284-91.
10. Khan AA, Diogenes A, Jeske NA, Henry MA, Akopian A, Hargreaves KM. Tumor necrosis factor alpha enhances the sensitivity of rat trigeminal neurons to capsaicin. *Neuroscience* 2008;155:503-9.
11. Khan AA, Sun X, Hargreaves KM. Effect of calcium hydroxide on proinflammatory cytokines and neuropeptides. *J Endod* 2008;34:1360-3.
12. Figini L, Lodi G, Gorni F, Gagliani M. Single versus multiple visits for endodontic treatment of permanent teeth. *Cochrane Database Syst Rev* 2007;CD005296.
13. Figini L, Lodi G, Gorni F, Gagliani M. Single versus multiple visits for endodontic treatment of permanent teeth: a Cochrane systematic review. *J Endod* 2008;34(9):1041-7.
14. Oguntebi BR, DeSchepper EJ, Taylor TS, White CL, Pink FE. Postoperative pain incidence related to the type of emergency treatment of symptomatic pulpitis. *Oral Surg Oral Med Oral Pathol* 1992;73:479-83.
15. Nyerere JW, Matee MI, Simon EN. Emergency pulpotomy in relieving acute dental pain among Tanzanian patients. *BMC Oral Health* 2006;6:1.
16. Hasselgren G, Reit C. Emergency pulpotomy: pain relieving effect with and without the use of sedative dressings. *J Endod* 1989;15:254-6.
17. Moos HL, Bramwell JD, Roahen JO. A comparison of pulpectomy alone versus pulpectomy with trephination for the relief of pain. *J Endod* 1996;22:422-5.
18. Torabinejad M, Cymerman JJ, Frankson M, Lemon RR, Maggio JD, Schilder H. Effectiveness of various medications on postoperative pain following complete instrumentation. *J Endod* 1994;20:345-54.
19. Hildebrand C, Fried K, Tuisku F, Johansson CS. Teeth and tooth nerves. *Prog Neurobiol* 1995;45:165-222.
20. McDougal RA, Delano EO, Caplan D, Sigurdsson A, Trope M. Success of an alternative for interim management of irreversible pulpitis. *J Am Dent Assoc* 2004;135:1707-12.
21. Nowicka A, Lipski M, Parafiniuk M, Sporniak-Tutak K, Lichota D, Kosierkiewicz A, et al. Response of human dental pulp capped with biodentine and mineral trioxide aggregate. *J Endod* 2013;39:743-7.
22. Lee M, Winkler J, Hartwell G, Stewart J, Caine R. Current trends in endodontic practice: emergency treatments and technological armamentarium. *J Endod* 2009;35:35-9.
23. Sjogren U, Hagglund B, Sundqvist G, Wing K. Factors affecting the long-term results of endodontic treatment. *J Endod*



- 
- 1990;16:498-504.
24. Siqueira JF, Jr., Lopes HP. Mechanisms of antimicrobial activity of calcium hydroxide: a critical review. *Int Endod J* 1999;32:361-9.
  25. Weine FS, Healey HJ, Theiss EP. Endodontic emergency dilemma: leave tooth open or keep it closed? *Oral Surg, Oral Med Oral Pathol* 1975;40:531-6.
  26. AAE, AAMOR. AAE and AAOMR Joint Position Statement: Use of Cone Beam Computed Tomography in Endodontics 2015 Update. *Oral Surg, Oral Med Oral Pathol Oral Radiol* 2015;120:508-12.
  27. Weine FS. The C-shaped mandibular second molar: incidence and other considerations. Members of the Arizona Endodontic Association. *J Endod* 1998;24:372-5.
  28. Lambrianidis T, Lyroudia K, Pandelidou O, Nicolaou A. Evaluation of periapical radiographs in the recognition of C-shaped mandibular second molars. *Int Endod J* 2001;34(6):458-462.
  29. Cooke HG, 3rd, Cox FL. C-shaped canal configurations in mandibular molars. *J Am Dent Assoc* 1979;99:836-9.
  30. Rosenberg PA, Babick PJ, Schertzer L, Leung A. The effect of occlusal reduction on pain after endodontic instrumentation. *J Endod* 1998;24:492-6.
  31. Smith EA, Marshall JG, Selph SS, Barker DR, Sedgley CM. Nonsteroidal Anti-inflammatory Drugs for Managing Postoperative Endodontic Pain in Patients Who Present with Preoperative Pain: A Systematic Review and Meta-analysis. *J Endod* 2017;43:7-15.
  32. Elzaki WM, Abubakr NH, Ziada HM, Ibrahim YE. Double-blind Randomized Placebo-controlled Clinical Trial of Efficiency of Nonsteroidal Anti-inflammatory Drugs in the Control of Post- endodontic Pain. *J Endod* 2016;42:835-42.
  33. Baumgartner JC, Xia T. Antibiotic susceptibility of bacteria associated with endodontic abscesses. *J Endod* 2003;29:44-7.
  34. Diogenes A, Ferraz CC, Akopian AN, Henry MA, Hargreaves KM. LPS sensitizes TRPV1 via activation of TLR4 in trigeminal sensory neurons. *J Dent Res* 2011;90:759-64.
  35. Ferraz CC, Henry MA, Hargreaves KM, Diogenes A. Lipopolysaccharide from *Porphyromonas gingivalis* sensitizes capsaicin-sensitive nociceptors. *J Endod* 2011;37:45-8.

The AAE wishes to thank Dr. Nikita B. Ruparel for authoring this issue of the newsletter, as well the following article reviewers: Drs. Mark B. Desrosiers, Steven J. Katz, Keith V. Krell, Garry L. Myers and Jaclyn F. Rivera.

# The Role of Calcium Hydroxide in the Healing of Periapical Lesion: A Case Report

Pauline Tiffany O. Uy, DMD  
Illuminada L. Vioria, DMD, PhD  
University of the East, College of Dentistry

## INTRODUCTION

Pulpal disease may result in the formation of periapical lesion which is the result of an infectious process or inflammatory response around the root of the tooth (1). More than 90% of periapical lesions can be classified as dental granulomas, radicular cysts or abscesses (2).

In teeth with chronic periapical lesion, root canal medicament is recommended to aid in the elimination of bacteria on areas that are not reached by instrumentation. Complex internal root anatomy like isthmuses that are not accessible to instrumentation can serve as a nidus of infection if not properly cleaned.

Calcium hydroxide is a widely used intracanal medicament due to its antimicrobial property. High pH of Calcium Hydroxide causes protein denaturation and damage to both DNA and cytoplasmic membrane of the bacteria which leads to bacterial death. Not only can Calcium Hydroxide deactivate endotoxin, which is the cause of inflammation and periapical bone loss, it can also promote hard tissue deposition (3).

Calcium hydroxide is generally used with three kinds of vehicle: aqueous, viscous and oily. Aqueous vehicle promotes highest degree of solubility and needs to be redressed several times throughout the treatment whereas oily vehicle has the least solubility and can remain in the canal for a longer period of time. In this case, Calcium Hydroxide in oily vehicle, Vitapex, was used.

Studies say that 7-day application of a  $\text{Ca}(\text{OH})_2$  medicament is enough to reduce canal bacteria to result in a negative culture, rendering 92.5% of canals bacteria free (3). In the study of Estrela, the complete inhibition of microorganisms including *E. faecalis* in infected canal occurs at 60 days (12).

## Case Report

A 23 year-old female patient was referred to the Endo-Perio Section due to an on and off pus formation for almost a year and the presence of big carious lesion and apical radiolucencies on the radiograph.

**History of Present Illness:** Two years prior to consultation (PTC), the patient has been having food impaction between tooth 36 and 38. Ten months PTC, the patient noticed that there was on and off pus formation coming out of the buccal gingiva somewhere between tooth 35 and 36. The patient didn't feel any sensitivity or pain or had any discomfort from tooth 36 prior to pus formation. Four months PTC, the patient no longer noticed pus formation. Two months PTC, the patient sought dental treatment at UE College of Dentistry. Oral prophylaxis was done and on March 10 2017, the patient underwent a more comprehensive workup in the oral medicine section.

**Diagnostic Tests:** Clinical examination revealed presence of caries in the occlusal pit and fissure and the buccal pit (Fig. 1). No sinus tract was seen on the buccal and lingual side of the gingiva around the tooth. Radiographically, there was a deep

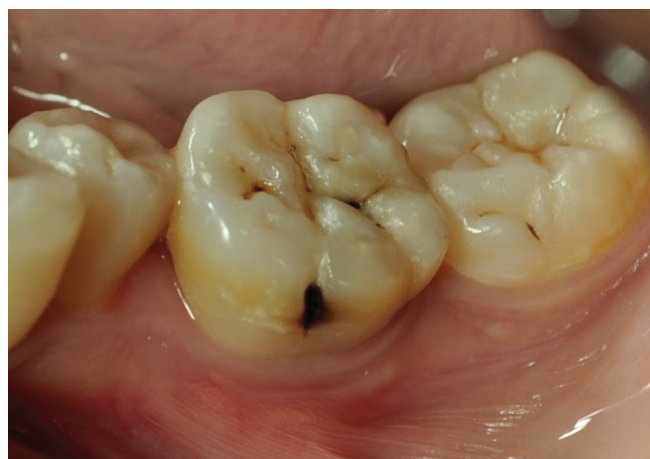

Figure 1. Pre-operative photograph of tooth 36.

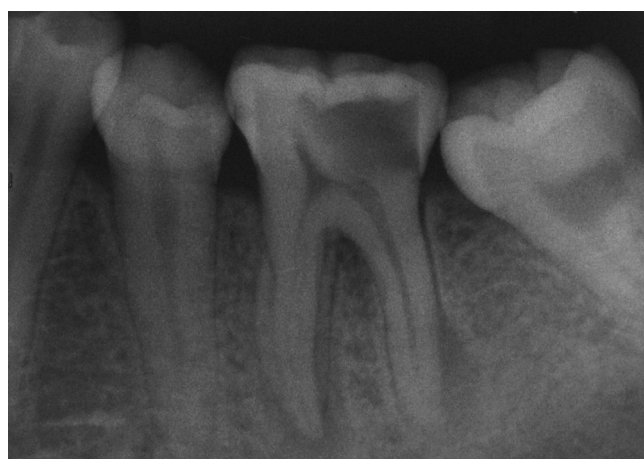

Figure 2. Pre-operative radiograph of tooth 36 showing big carious lesion.

carious lesion reaching the pulp with thin pulp chamber cervico-occlusally. The mesial canals were fine and exhibited slight curvature and apical radiolucencies were observed on both distal and mesial roots (Fig. 2). EPT result was 64 which confirmed that the tooth is non vital. Percussion and palpation tests on tooth 36 were both negative. There was no mobility. Probing depths were within normal limits.

**Diagnosis:** Necrotic Pulp and Asymptomatic apical periodontitis.

**Treatment Proper:** Treatment started towards the end of the semester in UECD. Initially, caries was removed, tooth was freed from occlusion, access preparation was done and orifices of the canals were located (Fig. 3). Sizes 08 and 10 (M-Access Dentsply) were used to establish the patency of the fine and narrow canals (Fig. 4) Working length was established with the aid of Tri-Auto ZX (J. Morita, Japan). Canal preparation was accomplished using Proglider and WaveOne Gold Small and Primary file (Maillefer, Dentsply) following the manufacturer's instruction. The tooth was irrigated with copious amount of 0.5% NaOCl after every file used and 15% EDTA (Glyde, Dentsply) was used during the entire procedure to facilitate easy file insertion and smear layer removal. Apical constriction was gauged with a 0.02 taper stainless steel file to determine the size of MAF after biomechanical preparation (Fig. 5) Calcium hydroxide was placed as intracanal medicament for a period of two and one half months, over the summer vacation and 4mm Cavit

(3M ESPE) was used as temporary filling (Fig. 6). When classes resumed the tooth was assessed for symptoms and integrity of the temporary filling prior to calcium hydroxide removal (Fig. 7). Apical gauging was done again to obtain the size of the master cone (Fig. 8). The tooth was obturated with .02 taper gutta-percha and slow setting ZOE (USP) using the lateral condensation technique. The gutta-percha were cut 1 mm below the root canal orifices and protected with 2mm GC Fuji VII as intra-orifice seal (Figs. 9, 10, 11). Choice of final restoration was indirect composite onlay using SDR Composite Resin with Ceram X Universal shade A3.5 as a capping composite (Fig. 12). Radiographs were taken from pre-operative, initial apical file, master apical file, calcium hydroxide placement, master cone, obturation and postoperative radiograph showing the final restoration (Fig. 13).

The patient came after two months to check the compliance in cleaning the food impaction area and radiograph was taken to evaluate healing of the periapical lesion (Fig. 14).

### CASE DISCUSSION

The patient was diagnosed with Necrotic pulp and Asymptomatic apical periodontitis. This is due to the result of EPT which is 64 and presence of apical radiolucencies without sinus tract.

Cariou lesion was removed to prevent contamination of the canals. To prevent gouging the floor of the chamber, size

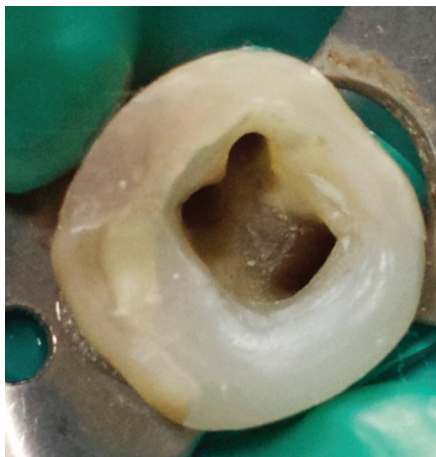

Figure 3. Completed access with Crown build up.

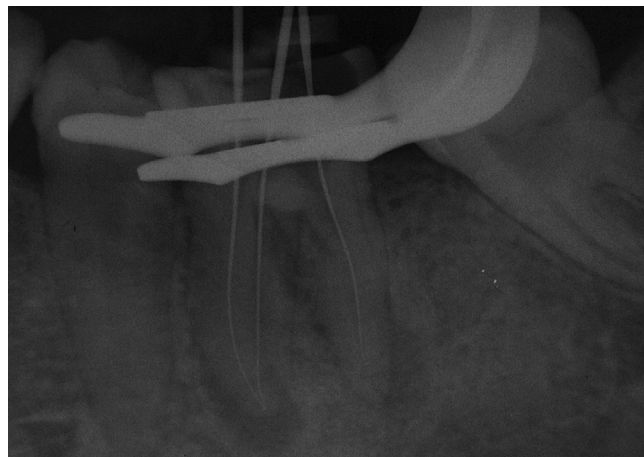


Figure 4. Patency files sizes 8 and 10.

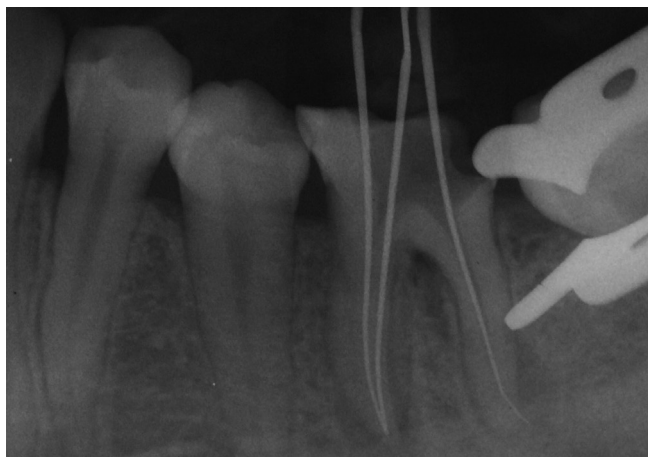

Figure 5. Master Apical Files of MB, ML, D canals.

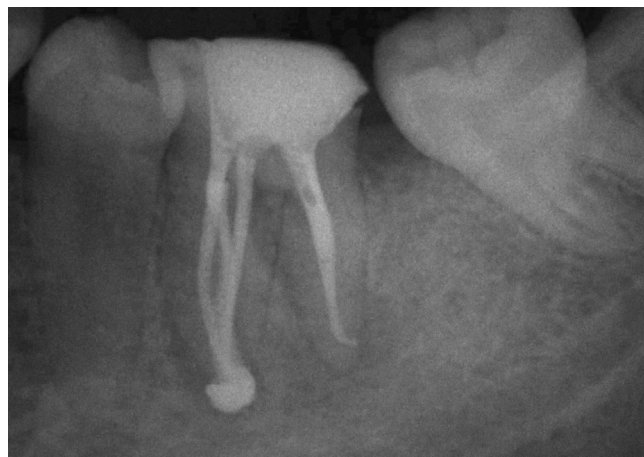

Figure 6. Immediately after Ca(OH)<sub>2</sub> placement.

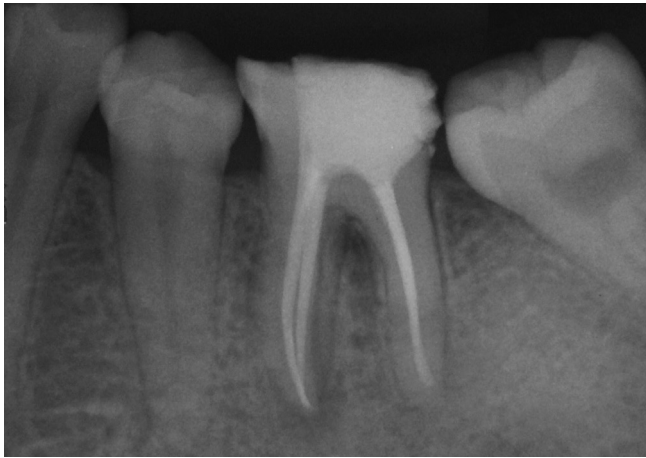

Figure 7. Two months and 24 days after Ca(OH)<sub>2</sub> placement.

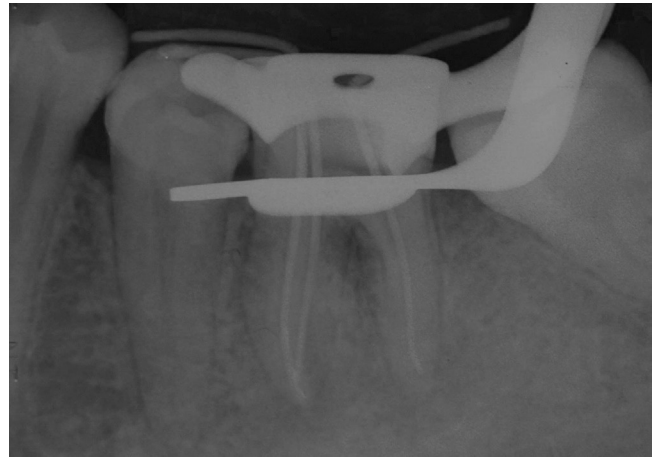

Figure 8. Master cone using .02 taper of GP.

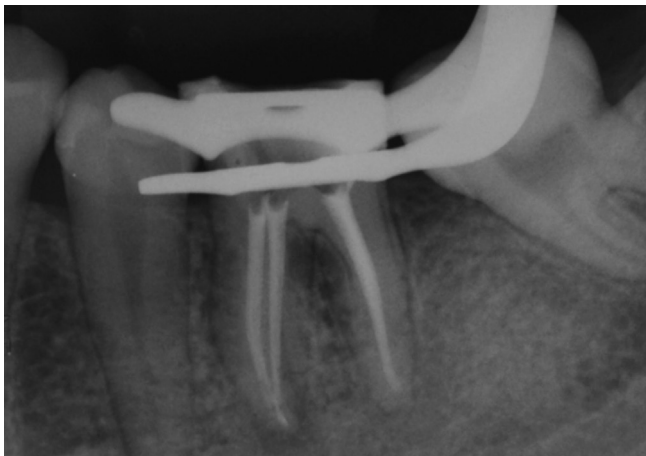


Figure 9. Obturated canals using lateral condensation technique.

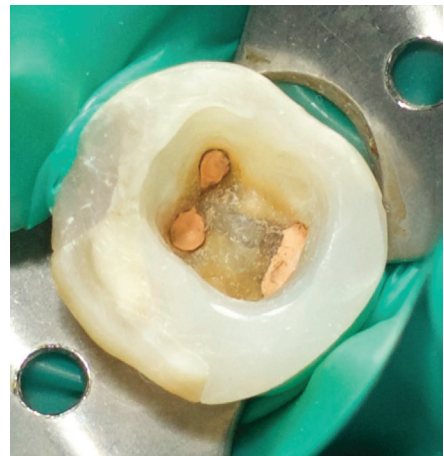

Figure 10. Cut gutta-percha.

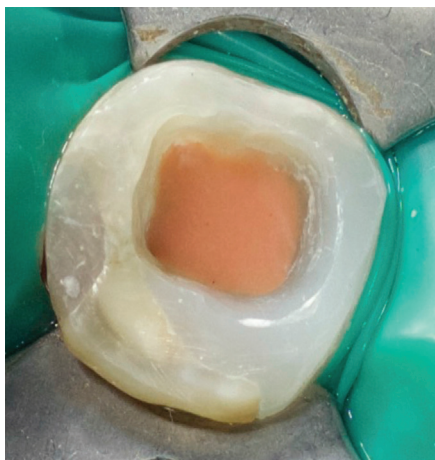


Figure 11. GIC on top of the gutta-percha.

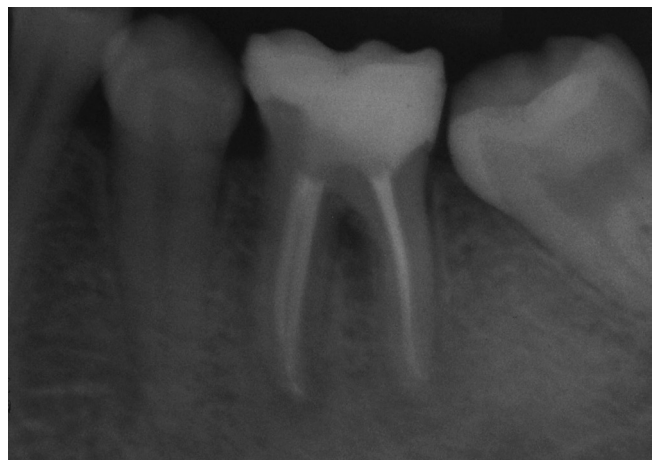
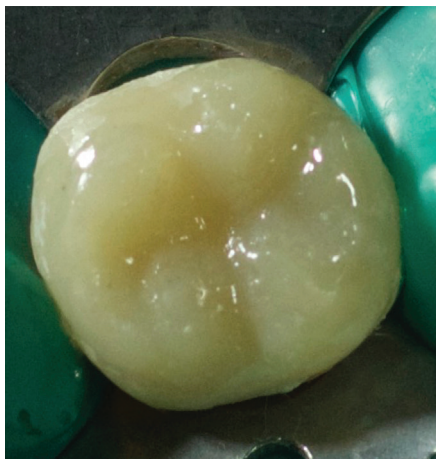
Figure 12. Radiograph of final restoration.



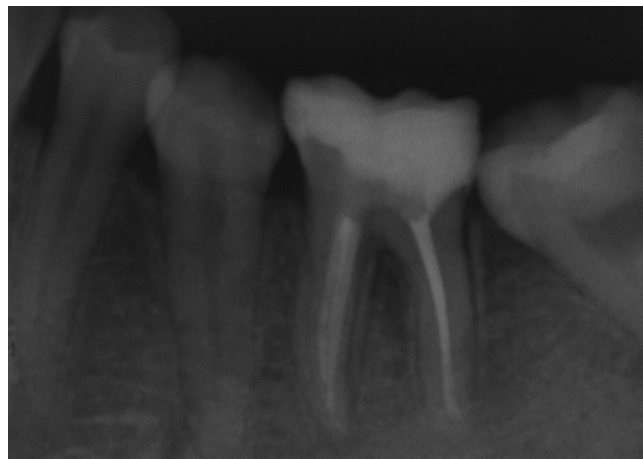**Figure 13. Clinical picture of final restoration.**

1/2 round bur was used to drop in. The selection of bur was done by superimposing the bur on the radiograph to make sure it fits the height of the pulp chamber. After completely unroofing the pulp chamber, orifices of MB, ML and D canals were located with endodontic explorer.

According to Young (5), Ni-Ti rotary instruments are not designed to negotiate canals without first using manual instrumentation due to its non-cutting tips and its extreme flexibility. Because of their greater stiffness, small stainless steel instruments should be used for path finding and to establish canal patency. Patency for all three canals were checked using M-access files and the length were established using Tri-Auto ZX (J. Morita) and verified with radiograph. All canals were enlarged up to a "super loose" size 10 before proceeding to Proglider. Proglider was the instrument of choice for enlarging the glide path and preflaring the canals because of its M-Wire technology. M-Wire is more flexible and more resistant to cyclic fatigue than regular Ni-Ti files therefore less likely to result in file separation which is the most common error during the use of Ni-Ti rotary instrument (6). After establishing a reproducible glide path with Proglider, WaveOne Gold was used according to the manufacturer's instructions. Eighty percent of the canals can be shaped with Primary file alone but when the Primary file doesn't passively advance to length Small file can be used as a bridge file. Although two file method is an exception, this method is still considered safer and more efficient than other rotary instrument techniques (7).

According to the study of Tikku (8), mesial root of the mandibular molar has 80% incidence of isthmus. EDTA 15% (Glyde™, Dentsply) was incorporated on the files for assistance during file insertion and lubrication. Isthmus was open up with EDTA and was cleaned with 0.5% NaOCl. Decreasing the concentration of the NaOCl reduces its antibacterial effect, ability to dissolve organic components and its toxicity (9). Based on the study of Young, GR. et al. (5), reduction of intracanal bacteria didn't show significant difference in using 5% and 0.5 % NaOCl irrigant as long as there is increase in frequency in rinsing the canal. Therefore, 0.5 % was used due to its lower tissue toxicity.

Calcium hydroxide (Vitapex) was placed as an intracanal medicament and temporization of the tooth was done with 4mm of Cavit (3M ESPE). In teeth with chronic apical



**Figure 14. Recall after 2 months.**

lesion, root canal medicament is recommended to aid in the elimination of bacteria on areas that are not reached by instrumentation (10). High pH of Ca(OH)<sub>2</sub> causes bacterial death and deactivates endotoxin (11). In the study of Estrela, complete inhibition of microorganisms including *E. faecalis* in infected canal occurred at 60 days after the use of Ca(OH)<sub>2</sub> (12). In this case, Ca(OH)<sub>2</sub> was placed for 2 months and 24 days. In the clinical case report of Mandhotra (13), Ca(OH)<sub>2</sub> formulations was intentionally pushed into the periapical lesions which led to the healing of the radiolucency within 18 months. Extrusion of Ca(OH)<sub>2</sub> might cause pain and swelling due to the response of the immune system. Mefenamic acid 500mg was prescribed.

At the start of the next semester, the tooth was assessed for symptoms, integrity of the temporary filling and radiograph was taken. Radiograph shows bone deposition on both mesial and distal roots. Calcium hydroxide was removed and the apices were gauged again with .02 taper M-access SS files to confirm the master cone size. Two percent taper gutta percha and slow set ZOE were used for obturation. Cold lateral condensation was the obturation technique. According to the study of Aqrabawi (14), no significant statistical difference was found between the outcome using lateral condensation and vertical compaction and in the study of Li Peng (15), lateral condensation exhibits more accurate length control. In another study, comparing Guttaflow, thermoplastized gutta percha and lateral condensation technique the mean comparative leakage scores were found to be insignificant (16).

Placement of a suitable material over the coronal gutta-percha to act as a barrier to coronal microleakage would be advantageous, GIC offers a higher sealing ability compared to composite at 1mm and 2mm (17).

Indirect composite onlay was done for final restoration because it prevents moisture control and allows better control of anatomy, contour, proximal contacts and occlusion (18). Polymerization shrinkage of the composite onlay will be limited to that of the luting resin (19). A layer of SDR was placed on top of the GIC Fuji 7 as a base for the restoration. Surefil SDR has relatively lower polymerization shrinkage and allows 4mm bulk placement in one layer (20). The anatomy of the tooth was built extraorally with aesthetic composite Ceram X Universal shade A3.5 then cemented with Calibra®

---

Esthetic Resin Cement. Indirect composite resin inlays and onlays placed with dual cure luting procedure exhibited a success rate of 90% according to the 10 year follow up study of Barabanti (21). Occlusion was checked and radiograph was taken to verify the marginal integrity of the final restoration.

## CONCLUSION

Significant healing of the periapical lesion was seen two months after the obturation. This can be attributed to proper

diagnosis, BMP using Proglider and Waveone gold, Ca(OH)<sub>2</sub> medication, good obturation and proper final restoration with good coronal seal.

Succeeding follow up is scheduled every 6 months to check the proper oral hygiene of the patient, integrity of the final restoration, signs and symptoms and complete healing of the periapical lesion.

## REFERENCES

1. Chapman, M. N., Nadgir, R. N., Akman, A. S., Saito, N., Sekiya, K., Kaneda, T., & Sakai, O. (2013). Periapical Lucency around the Tooth: Radiologic Evaluation and Differential Diagnosis. *RadioGraphics*,33(1). doi:10.1148/rg.331125172
2. Fernandes, M., & Ataide, I. (2010). Nonsurgical management of periapical lesions. *Journal of Conservative Dentistry*,13(4), 240. doi:10.4103/0972-0707.73384
3. Mohammadi, Z., & Dummer, P. M. Properties and applications of calcium hydroxide in endodontics and dental traumatology. *International Endodontic Journal*, 44(8), 697-730. doi:10.1111/j.1365-2591.2011.01886.x
4. Seema D., Ashutosh D., and Pravin K. Nonsurgical Treatment of Two Periapical Lesions with Calcium Hydroxide Using Two Different Vehicles, *Case Reports in Dentistry*, vol. 2014, Article ID 901497, 4 pages, 2014.
5. Young GR, Parashos P, Messer HH. The principles of techniques for cleaning root canals. *Aust Dental Journal* 2007; 52 Suppl1: S52-S63.
6. Cassim, I., van der Vyver, P.J. The importance of glide path preparation in endodontics : a consideration of instruments and literature. *South African Dent J*. 2013;68:322–327.
7. Webber J. Shaping canals with confidence: WaveOne GOLD single-file reciprocating system. *Roots*. 2015; 1:34-40
8. Tikku AP, Pandey PW, Shukla I. Intricate internal anatomy of teeth and its clinical significance in endodontics: A review. *Endodontology* 2012;24:160-9
9. Winter. Root Canal Irrigants and Disinfectants. 2011
10. Nelson Filho P, Leonardo MR, Silva LA, Assed S. Radiographic evaluation of the effect of endotoxin (LPS) plus calcium hydroxide on apical and periapical tissues of dogs. *J Endod*. 2002;28:694-6.
11. Leonardo MR, Silva RA, Assed S, Nelson-Filho P. Importance of bacterial endotoxin (LPS) in endodontics. *J Appl Oral Sci*. 2004;12:93–98.
12. Estrela c, Estrela c, Pécor j. A study of the time necessary for calcium hydroxide to eliminate microorganisms in infected canals. *J Appl Oral Sci* 2003; 11(2): 133-137
13. Mandhotra P, Goel M, Rai K, Verma S, Thakur V, Chandel N. Accelerated Non Surgical Healing of Large Periapical Lesions using different Calcium Hydroxide Formulations: A Case Series. *Int J Oral Health Med Res* 2016;3(4):79-83.
14. Aqrabawi JA. Outcome of Endodontic Treatment of Teeth Filled Using Lateral Condensation versus Vertical Compaction (Schilder's Technique). *J Contemp Dent Pract* 2006 February;(7)1:017-024.
15. Peng L, Ye L, Tan H, Zhou X. Outcome of root canal obturation by warm gutta-percha versus cold lateral condensation: a meta-analysis. *J Endod*. 2007;33:106-9
16. Kapoor V, Singh H, Bansal R, Paul S. Qualitative and Quantitative Comparative Evaluation of Sealing Ability of Guttaflow, Thermoplasticized Gutta Percha and Lateral Compaction for Root Canal Obturation: A Cohort, Controlled, ExVivo Study. *Oral Health Dent Manag* 2013;12: 505.
17. Salim, B., Hassan, N., Effect of different intra-orifice barriers in Endodontically treated teeth obturated with gutta-percha. *Scientific Article. IAJD Vol. 6 – Issue 3, 2015*
18. Rocea, G., Krejci, I. Crown and post-free adhesive restorations for endodontically treated posterior teeth: from direct composite to endocrowns. *Eur J Esthetic Dent* 2013; 8 92): 156-179.
19. McCarthy, R. The application of indirect composite onlays in the restoration of severely broken down posterior teeth. *J Ir Fent Assoc* 2015; 61 (6): 309-12.
20. Ilie N, Hickel R. Investigations on a methacrylate-based flowable composite based on the SDR™ technology. *Dental Materials* 2011;27:348–55.
21. Barabanti, N., Preti, A., Vano, M., Derchi, G., Mangani, F., Cerutti, A. Indirect composite restorations luted with two different procedures: a ten years follow up clinical trial. *J Clin Exp Dent*. 2015;7:e54–e59.

### About the Authors:

Pauline Tiffany O. Uy, DMD

University of the East

Top 1 Dental Licensure Examination December, 2017

Second Place Winner Dentsply Sirona Asia University Endodontic Case, 2017

Illuminada L. Vilorio, DMD, PhD

Professor, College of Dentistry

University of the East

# Case Report: Management of Mandibular Lateral Incisors with Vertucci Type II Canal Configuration

Subekchya Prasai, BDS  
Benjamin Simiyu Nyongesa, BDS  
Jennyleen Y. Sicat, DMD  
Kenny Tung, DMD  
Fredrick Weboko Ikhabhi, BDS

Katrina G. De Luna, DMD, MScD  
Grace Ellen S. Dey, DMD, MScD  
Illuminada L. Vilorio, DMD, PhD  
University of the East, College of Dentistry,  
Postgraduate Endodontic Section

## INTRODUCTION

A thorough knowledge of tooth morphology is a necessity for successful endodontic treatment (1). Access cavity preparation on mandibular incisors are difficult, due to its narrow pulp chamber (2). The determination of the presence of second canal and the location of the separation of the two canals are fundamentals for the clinician because missed canals were found to be concomitant with post-endodontic failure (3).

There are different techniques in determining extra canal in mandibular anterior teeth. First, radiograph of diagnostic quality taken in two angulations. A straight on and angle shot either mesial or distal shift. Second, presence of “fast break” should be taken into attention while evaluating the pre-operative radiographs. If the root canal abruptly seems to straighten or broaden or if the course cannot be outlined, the presence of a second canal should be suspected and expected (5). Third, when in doubt Cone Beam Computed Tomography (CBCT) has to be taken to confirm presence or absence of additional canal.

Fourth, during access cavity preparation, a lingual shelf must be eliminated to allow direct-line access. The shoulder or lingual shelf obscures the orifice to a second canal that, if present, is found immediately beneath it. Most mandibular lateral incisors have one root. Often a dentinal bridge is present that splits the root into two canals. The two canals typically join and exit through a single apical foramen, but they may persist as two separate canals (2). Fifth, the use of magnification and fibre optic illumination offers an incredible gain while localizing and treating extra canals (8).

During the initial placement of K-files in the canal, one may confront an obstruction and a deflection of the file to the labial or the lingual before it can be explored further. A great deal of tactile feel and precurving of the K-file tip will thus be imperative in the identification of a second canal (9).

Vertucci (10) described the intricate canal system and identified eight types of pulp space configurations. His study showed a single canal with 1 foramen in 70% of mandibular central incisors and in 75% of the mandibular lateral incisors. Miyashita et al (11) evaluated the root canal anatomy of 1085 lower incisors. They discovered 87.6% single canals from the pulp chamber to the apex. Green (12) found that 79% of 500 central and lateral mandibular incisors had 1 major canal with 1 apical foramen.

This case report presents the endodontic management of mandibular lateral incisors, each having Vertucci type II configuration.

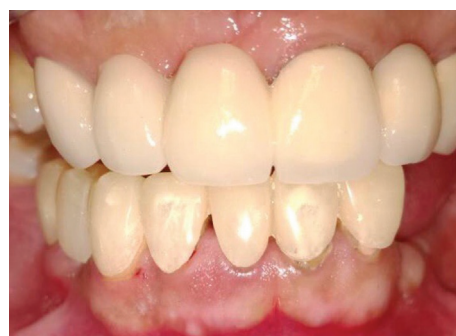Since such cases are common, they should be reported thereby aiding the clinicians to keep in mind the normal root canal morphology and anatomical disparities.

## Case History

A 41-year-old male patient reported to the Endodontic Section of University of the East College of Dentistry with the chief complaint of discomfort on biting on his lower front jaw one week prior to consultation.

History of present illness revealed intermittent spontaneous pain with hot and cold stimuli for the past few months. Past dental history revealed temporary crowns on all the four lower front teeth. The patient’s medical history was noncontributory.

On clinical examination, there were four temporary crowns made of acrylic (Fig. 1).

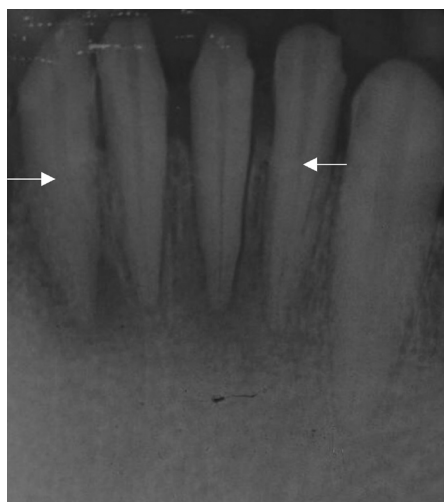


**Figure 1. Preoperative intraoral picture showing presence of acrylic crowns on the mandibular incisors (teeth numbers 42, 41, 31 and 32).**

Teeth numbers 41, 31 and 32 were tender to percussion with grade 1 mobility. Oral hygiene was fair with periodontal pocket depth within physiological limits.

After the removal of temporary crowns, thermal testing with Friljet (Pierre Rolland) and heated gutta-percha elicited a negative response on tooth 42 and 31. Teeth numbers 32 and 41 had a hypersensitive response to cold test. A diagnostic radiograph revealed a periapical radiolucency on 42 and 31 whereas widening of periodontal ligament on 41 and 32.

The radiograph also revealed unusual anatomy of 42 and 32 revealing a “fast break” (Fig. 2).



**Figure 2. Preoperative radiograph showing periapical radiolucency of 42 and 31 and widening of the periodontal ligament of the 41 and 32. Note the sudden narrowing or a disappearing pulp space on 42 and 32 (arrows).**

On the basis of the clinical and radiographic findings, the diagnosis for tooth 42 and 31 was Pulp Necrosis with Asymptomatic Apical Periodontitis and for teeth numbers 41 and 32, Symptomatic Irreversible Pulpitis with symptomatic apical periodontitis.

Root canal treatment was scheduled and initiated after obtaining written informed consent from the patient.

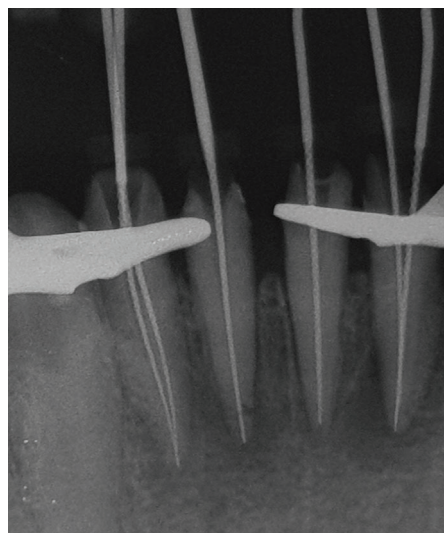
#### **Treatment Proper Procedure**

The acrylic crowns were removed using a crown remover. Local anaesthesia was administered via mental block using 1.8 ml of 2% Lignocaine with 1: 200,000 epinephrine. The teeth were isolated with a rubber dam and coronal access preparation of 31, 32, 41, and 42 was done using endo-access bur (Dentsply Sirona). The access cavity was then modified and extended buccolingually to the cingulum which revealed the presence of a lingual canal on 32 and 42. The working length was registered with Root ZX Mini apex locator (J. Morita, Japan) which was confirmed later with a radiograph (Fig. 3).

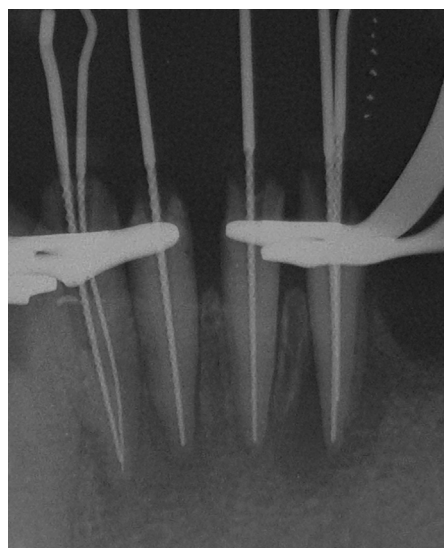
The canals were enlarged up to ISO size 15 K file (MANI, Japan) prior to the use of rotary files. Biomechanical Preparation was accomplished using TriAuto Mini endodontic motor (J. Morita, Japan) and Protaper Next Rotary instruments (Dentsply Maillefer) following the manufacturer’s instructions. A concentration of 17% of ethylenediaminetetraacetic acid (Glyde, Dentsply) was used as a lubricant (13–15)(21–23) and 5.2% of sodium hypochlorite as irrigant (16–19)(24–27).

After preparing the canals up to the rotary file no X2, gauging with hand files was done to determine the size of the apical constriction. A periapical radiograph was taken with the master apical files in situ (Fig. 4).

Considering the time taken to complete the therapy, the teeth were completed in two visits. After the biomechanical



**Figure 3. A radiograph showing the two canals on the mandibular lateral incisors.**



**Figure 4. Master Apical File (MAF) radiograph using 2% taper hand files.**

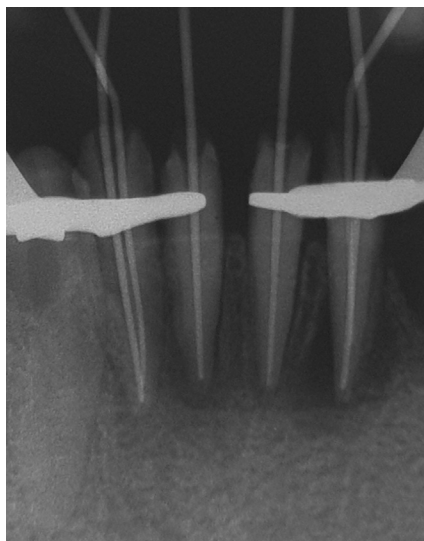
preparation of all the teeth, the root canals were dried with paper points and a paste of calcium hydroxide with iodoform (Meta Biomed) was used as intracanal medication. A sterile cotton pellet was placed in the pulp chamber of each tooth and a provisional restoration of Cavit (3M ESPE) was placed and the acrylic crowns temporally cemented in between visits.

After one week, the patient came back for the second appointment. The teeth were completely asymptomatic. The criteria for obturation was checked and a master cone radiograph was taken (Fig. 5).

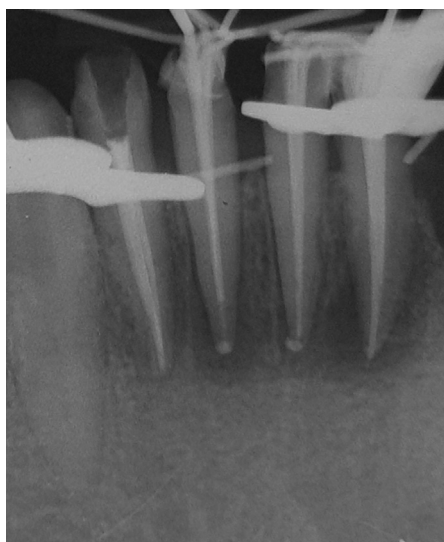The canals were then flushed with distilled water to remove sodium hypochlorite irrigant and was agitated with 17% EDTA solution for one minute. Distilled water was irrigated in the canal to wash off the EDTA solution. A final rinse with 5.25% sodium hypochlorite was done (30) and then flushed with distilled water to remove any traces of sodium hypochlorite in the root canals. The canals were then dried with sterile paper points. Obturation was accomplished using 2% taper gutta percha cones and Endoseal (PrevestDenPro)



sealer cement employing the cold lateral compaction technique. A radiograph was taken to confirm the quality of obturation (Fig. 6).



**Figure 5. Master Apical Cone(MAC) radiograph.**



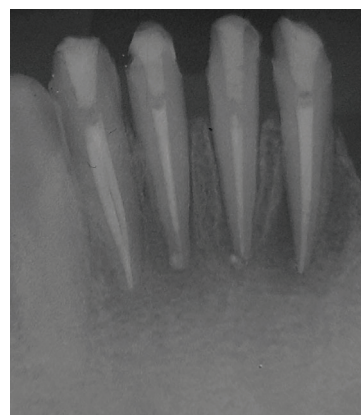
**Figure 6. The obturated canals.**

The Gutta percha cones were cut 2mm apical to the cemento-enamel junction (CEJ) and Glass Ionomer cement, GIC Fuji VII (GC Dental, Japan) was placed on top of the gutta percha to prevent coronal microleakage(2,31). The teeth were restored using a resin composite (BEAUTIFILL II, Shofu Dental Corporation) as per the manufacturer's instructions. The acrylic crowns were recemented and the patient was referred to the Prosthodontic Department for final restoration. The final radiograph showed a well-obturated canals of the incisors (Fig. 7).

## DISCUSSION

Accurate diagnosis and proper knowledge of the tooth anatomy are key to success of endodontic treatment (10,12,32). In this case, intraoral periapical radiographs played an imperative role in determining the internal anatomy of the teeth. The "fast break" was taken into attention. The access cavity was then modified and extended buccolingually to the cingulum which revealed the presence of a lingual canal on 32 and 42 (2).

A patency file is a small K-file (usually a size #10 or #15) that is passively extended slightly beyond the apical foramen.



**Figure 7. A final radiograph with composite restoration on the access cavities.**

The use of a patency file has been advocated for most rotary techniques. This step is alleged to eradicate accumulated debris, to help maintain working length, and to translate into greater clinical success (2,33). Achieving patency significantly increases the chance of endodontic success twofold (33). In this case report, patency was done up to ISO size 15 K file (MANI, Japan).

Current research suggests that mechanical properties of Protaper Next instruments, manufactured from M-Wire are handy during biomechanical instrumentation (34–36). In the present study, Protaper Next rotary files (Dentsply Sirona) were used for instrumentation.

Similar to other studies, 17% EDTA solution was irrigated in the canals and agitated for one minute to chelate with Ca<sup>2+</sup> and other divalent cations, demineralize the dentin, and remove the inorganic components of the smear layer (28,29). A final rinse with 5.25% sodium hypochlorite was done (30) and then flushed with distilled water to remove any traces of sodium hypochlorite in the root canals.

Lateral compaction was used to obturate the teeth. This is a common method for obturation (2,37) and can be used in most clinical situations because it provides for predictable length control during compaction (38). Glass Ionomer cement, GIC Fuji VII (GC Dental, Japan) was introduced into the canal orifices as a seal to prevent coronal microleakage (2,31) and the teeth restored with a composite restoration as a coronal seal (2).

This case report showed the two canals merging into a single canal. This is similar to Vandana et. al and other reports in which all lower incisors, each having two distinct canals amalgamated into a single canal before exiting the tooth via a single apical foramen (39–42).

This paper also presents successful identification of two canals in mandibular lateral incisors in the same patient. Because this morphological variant is about 11%-70% (13–20), such cases should be reported thereby enabling the clinicians to keep in mind the normal morphology and anatomical variations.

## CONCLUSION

The failure of an endodontic treatment is mainly due to inability to locate an extra canals and failure to treat it. The practitioner should have proper knowledge on the root canal anatomy and do a careful interpretation of the radiograph

before starting the root canal treatment. Good access cavity preparation, patency filing, accurate working length, proper biomechanical preparation and quality obturation with a coronal seal are key to successful endodontic treatment of teeth.

## REFERENCES

1. Krasner P, Rankow HJ. Anatomy of pulp-chamber floor. *J Endod* 2004;30:5–16.
2. Hargreaves KM, Berman LH. *Cohen's Pathways of the Pulp*. 11th Edition, Elsevier Health Sciences; 2016.
3. Karabucak B, Bunes A, Chehoud C, et al. Prevalence of apical periodontitis in endodontically treated premolars and molars with untreated canal: a cone-beam computed tomography study. *J Endod* 2016;42:538–41.
4. Sieraski SM, Taylor GN, Kohn RA. Identification and endodontic management of three-canal maxillary premolars. *J Endod*. 1989;15:29–32.
5. Theruvil R, Ganesh C, George AC. Endodontic management of a maxillary first and second premolar with three canals. *J Conserv Dent*. 2014;17(1):88–91.
6. Weine FS. 3rd ed. St Louis: The CV Mosby Company; 1982. *Endodontic Therapy*; pp. 207–55.
7. Vertucci FJ. Root canal anatomy of the mandibular anterior teeth. *J Am Dent Assoc* 1974;89:369–71.
8. Miyashita M, Kasahara E, Yasuda E, et al. Root canal system of the mandibular incisor. *J Endod* 1997;23:479–84.
9. Green D. Double canals in single roots. *Oral Surg Oral Med Oral Pathol* 1973;35:689–96.
10. Benjamin KA, Dowson J. Incidence of two root canals in human mandibular incisor teeth. *Oral Surg Oral Med Oral Pathol* 1974;38:122–6.
11. Kartal N, Yanikoglu FC. Root canal morphology of mandibular incisors. *J Endod* 1992;18:562–4.
12. Rankine-Wilson RW, Henry P. The Bifurcated Root Canal in Lower Anterior Teeth. *J Am Dent Assoc* 1965;70:1162–5.
13. Sert S, Bayirli GS. Evaluation of the root canal configurations of the mandibular and maxillary permanent teeth by gender in the Turkish population. *J Endod* 2004;30:391–8.
14. Caliskan MK, Pehlivan Y, Sepetcioglu F, Turkun M, Tuncer SS. Root canal morphology of human permanent teeth in a Turkish population. *J Endod* 1995;21:200–4.
15. Vertucci FJ. Root canal anatomy of the human permanent teeth. *Oral Surg Oral Med Oral Pathol* 1984;58:589–99.
16. de Oliveira SH, de Moraes LC, Faig-Leite H, Camargo SE, Camargo CH. In vitro incidence of root canal bifurcation in mandibular incisors by radiovisography. *J Appl Oral Sci* 2009;17:234–9.
17. Rahimi S, Milani AS, Shahi S, et al. Prevalence of two root canals in human mandibular anterior teeth in an Iranian population. *Indian J Dent Res* 2013;24:234–6.
18. B.N. Nygaard-Ostby. Chelation in root canal therapy: ethylenediamine tetra-acetic acid for cleansing and widening of root canals *Odontologisk Tidskrift*, 65 (1957), pp. 3–11.
19. R. Garberoglio, C. Becce. Smear layer removal by root canal irrigants *Oral Surgery, Oral Medicine, Oral Pathology*, 78 (1994), pp. 358–366.
20. O.A. Peters, C. Boessler, M. Zehnder. Effect of liquid and paste-type lubricants on torque values during simulated rotary root canal instrumentation *International Endodontic Journal*, 38 (2005), pp. 223–229.
21. Gomes BP, Ferraz CC, Vianna ME, Berber VB, Teixeira FB, Souza FJ. In vitro antimicrobial activity of several concentrations of sodium hypochlorite and chlorhexidine gluconate in the elimination of *Enterococcus faecalis*. *Int Endod J*, 2001; 34: 424–428.
22. Radcliffe CE, Potouridou L, Qureshi R, Habaheh N, Qualtrough A. Antimicrobial activity of varying concentrations of sodium hypochlorite on the endodontic microorganisms *Actinomyces israelii*, *A. naeslundii*, *Candida albicans* and *Enterococcus faecalis*. *Int Endo J*, 2004; 37: 438–446.
23. Zehnder M. Root canal irrigants. *End J*, 2006; 32: 389–398.
24. Mammani IMA and Saleh ZE. Efficacy of Endox Endodontic System in eradication of *Enterococcus faecalis* from Infected Pulp in Duhok, Kurdistan, Iraq. *Rawal Med J*, 2010; 35: 48–5.
25. Baumgartner JC, Mader CL. A scanning electron microscopic evaluation of four root canal irrigation regimens. *J Endodon* 1987;13:147–57.
26. Yamada RS, Armas A, Goldman M, Lin PS. A scanning electron microscopic comparison of a high volume final flush with several irrigating solutions. Part 3. *J Endodon* 1983;9:137–42.
27. Goldman M, Goldman LB, Cavaleri R, Bogis J, Lin PS. The efficacy of several endodontic irrigating solutions: a scanning electron microscopic study. Part 2. *J Endodon* 1982;8:487–92.
28. Pisano DM, DiFiore PM, McClanahan SB, et al: Intraorifice sealing of gutta-percha obturated root canals to prevent coronal microleakage, *J Endod* 24:659, 1998.
29. Hess W. *The anatomy of the root canals of teeth of the permanent dentition*. New York: Williams Wood Co.; 1925.
30. Ng YL, Mann V, Gulabivala K: A prospective study of the factors affecting outcomes of nonsurgical root canal treatment: part 1: periapical health, *Int Endod J* 44:583, 2011.
31. Arias A, Singh R, Peters OA: Torque and force induced by ProTaper Universal and ProTaper Next during shaping of large and small root canals in extracted teeth, *J Endod* 40:973, 2014.
32. Elnaghy AM: Cyclic fatigue resistance of ProTaper Next nickel-titanium rotary files, *Int Endod J* 47:1034, 2014.
33. Pereira ESJ, Singh R, Arias A, Peters OA: In vitro assessment of torque and force generated by novel ProTaper Next Instruments during simulated canal preparation, *J Endod* 39:1615, 2013.

- 
34. Cailleateau JG, Mullaney TP: Prevalence of teaching apical patency and various instrumentation and obturation.
  35. Gilhooly RM, Hayes SJ, Bryant ST, et al: Comparison of lateral condensation and thermomechanically compacted warm alpha-phase gutta-percha with a single cone for obturating curved root canals, *Oral Surg Oral Med Oral Pathol Oral Radiol Endod* 91:89, 2001.
  36. Vandana B. Kokane, Swapnil N. Patil, Mohit K. Gunwal, Rajesh Kubde, and Swaraj Atre. Treatment of Two Canals in All Mandibular Incisor Teeth in the Same Patient. *Case Reports in Dentistry*, Volume 2014, Article ID 893980.
  37. V. Hegde, S. Kokate, and Y. Shahu, "An unusual presentation of all the 4 mandibular incisors having 2 root canals in a single patient—a case report," *Endodontology*, vol. 22, no. 2, pp. 70–74, 2010.
  38. A. M. Tiku, R. R. Kalaskar, and S. G. Damle, "An unusual presentation of all the mandibular anterior teeth with two root canals—a case report," *Journal of Indian Society of Pedodontics and Preventive Dentistry*, vol. 23, no. 4, pp. 204–206, 2005.
  39. S. Mattigatti, R. R. Mahaparale, R. V. Chopade, and V. Garg, "Unusual canal morphology in all mandibular incisors in a single patient," *International Journal of Dental Case Reports*, vol. 2, no. 3, pp. 72–76, 2012.

#### **Conflict of Interest**

The authors had full freedom of investigation and there were no potential conflicts of interest.

#### **Acknowledgements**

The Authors wish to thank Dr. Lyndel Joy Rana and Dr. Paula Andrea Mangune for their invaluable input during the preparation of this case. We would like to also acknowledge the Department of Endodontics, University of the East for allowing us to conduct this case study.

---

# Influence of Root Canal Sealers in Calcification

Grace Ellen S. Dey, DMD, MScD  
Rosario R. Buery, DMD, PhD  
University of the East

## INTRODUCTION

Root canal treatment following the standard clinical principles of thorough cleaning and shaping, disinfection and obturation will yield to a high treatment success rate (1). Three dimensional sealing is crucial to prevent reinfection of the canal and to preserve the health of the periapical tissues. Root canal (RC) sealers used during obturation is vital as it increases the possibility of attaining a fluid-tight seal and serves as a filler of the intricate root canal system in the presence of minor discrepancies between the canal wall and gutta percha (2). Aside from having good sealing ability, endodontic sealers should have adequate biological and physicochemical properties to promote favorable healing of the surrounding tissues by initiating bone deposition.

Fibroblasts provide important positional cues for wound healing and regeneration of tissues (3). Moreover, fibroblasts derived from the human periapical granulation tissues have the potential to differentiate into mature cells and produce calcified deposits in vitro (4). During the process, these cells synthesize genes which act as instructions to make proteins. Two of the most common genes expressed during calcification are alkaline phosphatase (ALP) and osteopontin (OPN). ALP is a common marker of osteoblastic activity (5) and OPN regulates the formation and remodeling of mineralized tissues (6). The common sealers currently used in clinical practice are calcium hydroxide, resin, and zinc oxide eugenol endodontic sealers. Selection of a sealer can influence the outcome of root canal treatment (7).

Calcium hydroxide can neutralize microbial organic debris and can induce repair with mineralized tissue deposition (8, 9). The advantages of resin based sealers are low solubility and disintegration, radiopacity, high bonding strength to root dentin, adequate expansion (10) and antimicrobial activity (11). On the other hand, zinc oxide eugenol based sealers have been used clinically for several decades due to their satisfactory physicochemical properties (12).

In order to determine the effect of RC sealers on the ability of the human periodontal ligament fibroblast (HPDLF) to initiate calcification, an in vitro study was made on the three most common RC sealers. The ability of HPDLF to produce calcification was determined by quantitative gene expression as well as gross staining of the calcified deposits.

## Materials and Methods

### Cell culture

HPDLF harvested from human premolars and maintained in the Cell and Tissue Culture Laboratory of the Science and Technology Research Center of De La Salle University were used in the study. The cells were cultured in alpha modified eagle medium ( $\alpha$ -MEM) containing 10% fetal bovine serum (FBS, Gibco, CA, USA) and 1% antibiotics (Antibiotic-Antimycotic, Gibco).

Cells were incubated at 37°C until the cells became confluent. After confluence, the cells were washed with phosphate buffered saline solution (PBS) and treated with 5% trypsin-ethylene diamine tetra acetic acid (EDTA). After centrifugation, cells were harvested and counted using Neubauer hemocytometer by trypan blue exclusion. A total cell count of  $1 \times 10^5$  cells/well was plated in a 96-well plate.

### Grouping of Samples

Serial dilution of RC sealers was carried out following the methodology of Mehran (13). Then after, the samples were grouped according to the RC sealers tested. Group A - HPDLF only (control group); Group B - HPDLF + AH Plus (DENTSPLY De Trey GmbH, 78467 Konstanz, Germany); Group C - HPDLF + Sealapex (SybronEndo – Sybron Dental Specialties, Glendora, CA, USA) and Group D - HPDLF + ZOE USP (Sultan Healthcare, York PA, USA). The samples were incubated for 7 and 14 days and culture medium was changed on the 4<sup>th</sup> day of the experimental period. All samples were done in triplicates.

### Quantitative determination of gene expression

#### Total RNA Extraction

After 7 and 14 days, total RNA was extracted following the manufacturer's instructions (RNEasy Minikit, Qiagen, USA) and concentrations were quantified by spectrophotometry machine (ELx800 Plate Reader, Bio Tek Instruments, USA).

#### Quantitative Polymerase Chain Reaction (Q-PCR)

Q-PCR was done using One-step KAPA Fast SYBR Green (KAPA Biosystems). A total volume of 20  $\mu$ L containing 1  $\mu$ L of mRNA, 0.2  $\mu$ M of each forward and reverse primers and DEPC water were made in each PCR tube.

Samples were placed in real time Thermocycler using the following PCR conditions: reverse transcription at 50°C for 3 mins, followed by 40 cycles of denaturation at 94°C for 30 sec, annealing of 50°C (after optimization) for 30 sec, extension at 72°C for 30 sec and an additional extension at 72°C for 1 min. Human GAPDH cDNA was simultaneously quantified using

OPN	*CCCTTCCAAGTAAGTCCAACGAAAGC (forward)
	*CTGGATGTCAGGTCTGCGAAACTT (reverse)
ALP	**CTGCCATCCTGTATGGCAATG (forward)
	**AGACTGCGCCTGGTAGTTGTTG (reverse)

**Table 1. Primer design.**

Corbett RG 3000 software (Rotor-Gene 6.1.93) at internal standard concentrations which would be a reference for the quantitation of transcript levels. All samples were done in duplicates.

**Calcification Assay**

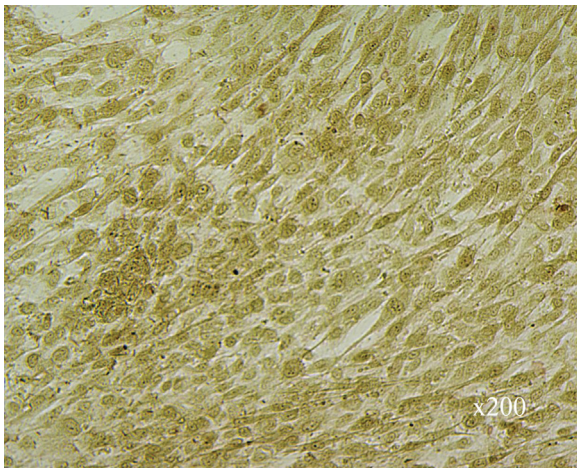
Calcification assay was adopted following the methodology of Rodriguez et al. (14). After 7 and 14 days, culture dishes were washed with PBS once and then fixed with 95% ethanol at 37°C for 15 min. Then after, the cells were washed with distilled water and then stained with 1% Alizarin Red S (ARS) (Kanayama Chemical, Japan) solution for 5 min. Excess dye was washed 3x with distilled water and the samples were examined by phase microscopy using an inverted microscope.

**Results**

**Cell Culture of HPDLF**

HPDLF reached confluence on day 4. However, on day 7, the fibroblasts increased in number. The cells were fusiform, spindle or polygonal in shape typical of human periodontal ligament fibroblasts (Fig. 1).

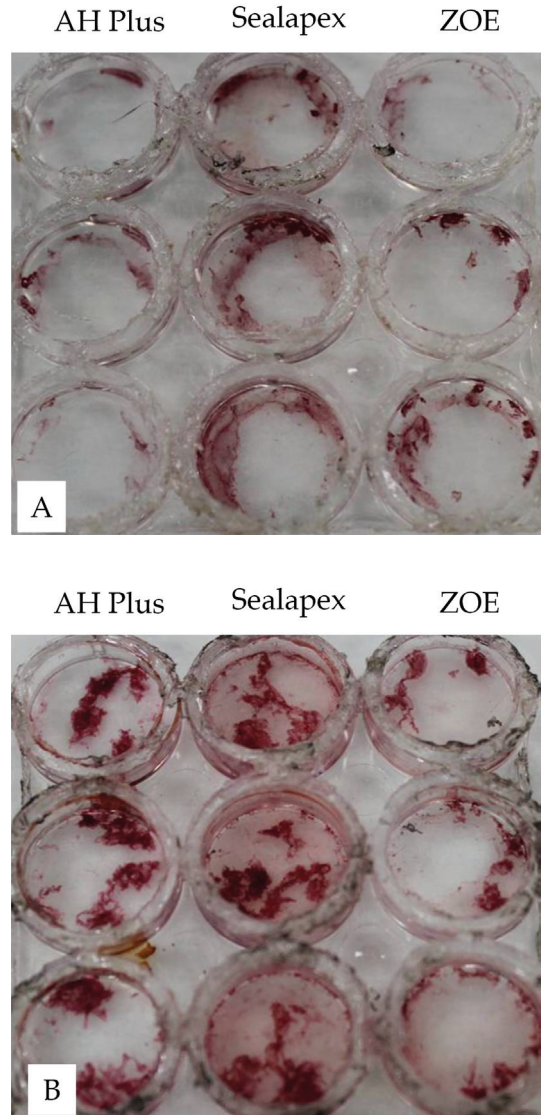
**Calcification Assay**



**Figure 1. Phase contrast micrograph of HPDLF at day 7.**

ARS staining was carried out to determine the formation of calcification at day 7 and 14. Each well was treated with ARS and calcification was noted by the formation of red nodules visualized macroscopically. Samples showed variously sized and distinct nodules deposited by HPDLF (Fig. 2). At day 7, few calcified deposits were stained on Sealapex whereas the calcified deposits on AH Plus and ZOE were very weakly stained. However at day 14, a significant difference was observed among the sealers. Calcified deposits produced on Sealapex displayed strong staining followed by AH Plus

while ZOE produced weakest staining. Calcified deposits were more numerous and larger in day 14 compared to day 7 in all RC sealers. No calcified deposits were observed in the control group (figure not shown).



**Figure 2. Alizarin Red S Staining showing calcification formed at day 7 (2A) and day 14 (2B).**

**Microscopic Calcification**

Microscopic calcification was also analyzed using phase contrast microscope at day 14. AH Plus showed a large and wide area of calcification (Fig. 3A), whereas Sealapex had numerous and larger stained nodules with wider coverage of calcification (Fig. 3B). ZOE samples demonstrated few stained nodules with some form of calcification (Fig. 3C).

**ALP and OPN Gene Expressions**

Figure 4 and 5 show the log copies ALP and OPN in three RC sealers. ALP and OPN were not expressed by HPDLF in ZOE group at day 7 and 14. However, both genes were expressed by HPDLF in Sealapex and AH Plus groups at day 7 and 14. The HPDLF with Sealapex obtained the highest log copies for both genes. A significant difference between Sealapex and AH Plus was obtained for both ALP and OPN gene expressions at day 7 and at day 14. No gene expression was obtained in the control group.

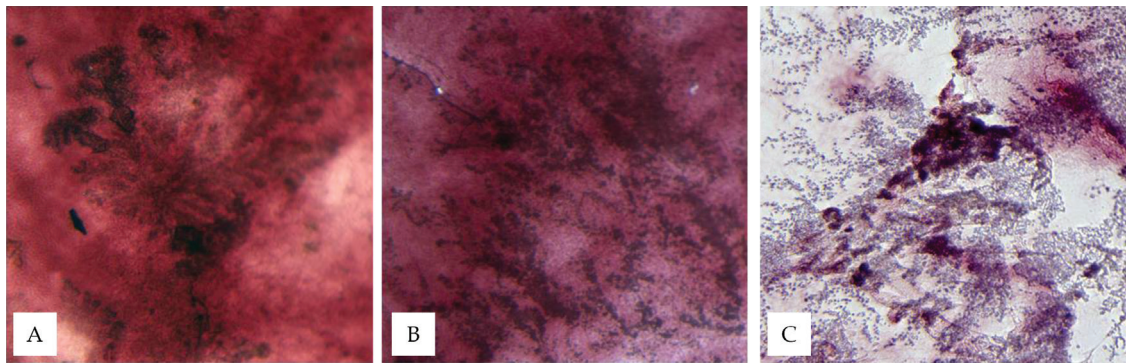


Figure 3. Microscopic appearance of samples treated with AH Plus (3A), Sealapex (3B) and ZOE (3C) at day 14 (6x).

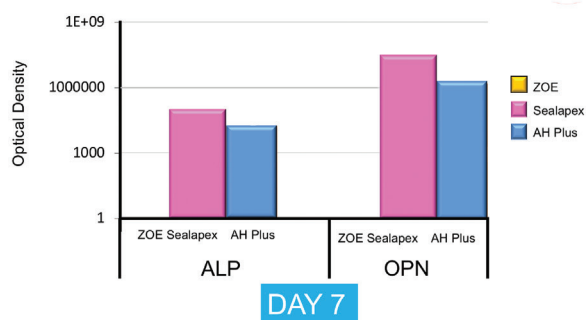


Figure 4. ALP and OPN expressions at day 7. ALP and OPN were not expressed in ZOE but were detected in AH Plus and Sealapex ( $p < 0.05$ ).

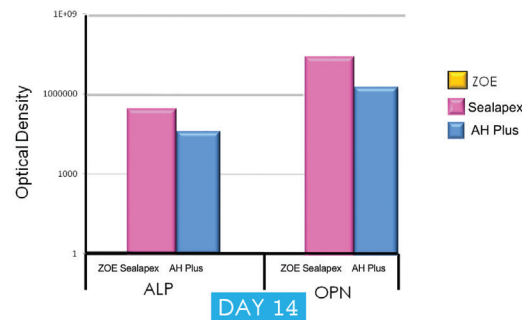


Figure 5. ALP and OPN expressions at day 14. ALP and OPN were not expressed in ZOE but were detected in AH Plus and Sealapex ( $p < 0.05$ ).

Student's t-test was performed to analyze the differences within and between groups by determining the  $p$ -value at 95% confidence interval. A  $p$ -value of 0.05 or less was considered statistically significant.

## DISCUSSION

Sealers play an important role in maintaining and promoting periapical tissue healing. Healing of the periapical tissue can be determined by bone deposition produced by the periodontal ligament cells. Bone regeneration, resumption of an intact periodontal ligament space and deposition of cementum around the root apex are the essential components of periapical tissue healing after root canal treatment. The periodontal ligament (PDL) contains a unique assortment of fibroblasts. Some studies proposed that PDL fibroblasts can differentiate into osteoblasts or cementoblasts and are implicated in the regeneration of alveolar bone, cementum, and PDL (15) (16). HPDLF are known to participate in calcification. Using three different RC sealers, the ability to induce calcification was observed using ARS to assess calcium rich deposits in culture (17). ARS identified the development of mineralized nodules in culture produced by HPDLF in the presence of RC sealers. To further confirm the mineralization process caused by HPDLF, genetic markers of calcification ALP and OPN were analyzed.

The exposure of HPDLF to Sealapex and AH Plus upregulated ALP gene activity on day 7 and 14. Carlson et al established that a progressive elevation in OPN expression was detected in diseased and traumatized sites (18) and there are evidences documented that OPN secreted by macrophages appear to mediate cell attachment serving as a prerequisite to tissue repair (19) (20).

Results of this study clearly displayed the OPN gene expression on day 7 and continuous increase on day 14 for both Sealapex and AH Plus compared to the control and ZOE. This elevated OPN expression observed in cell cultures is indicative of the presence of osteoblasts differentiated from HPDLF responsible for calcification and early phase of mineralization.

Calcium hydroxide is a component of Sealapex while AH Plus contains calcium tungstate. Da Silva et al. (21) noted that exposure of sealers with calcium to an aqueous media causes the release of calcium ions during ionic dissociation. Furthermore, the amount of free calcium ions determines its capacity to induce mineralized tissue. Similarly, other studies revealed that the free calcium ions initiate the stimulation of calcium-dependent adenosine triphosphatase associated with hard tissue formation (22). When components of sealers leached out, the surrounding tissues respond in a manner that might be advantageous to encourage tissue repair. Previous investigations proved that these calcium ions are reported to be required for cell migration, differentiation, and mineralization (23) (24). However, the hydroxyl group of ions in calcium hydroxide renders it antibacterial due to its very high pH. Studies show that the high pH of calcium hydroxide neutralizes lactic acid from osteoclasts and prevents dissolution of mineralized components of teeth likewise its high alkaline nature activates the ALP which encourages repair and active calcification (25) (26). Recent investigation has shown that there was a significant difference in the pH of Sealapex as compared to AH Plus. Finger et al. stated that there was a steady increase in the pH value for Sealapex over time, starting with a pH of 10.2 after 3 hours, increasing to 11.5 after 24 hours and reaching 11.1 after 168 hours. However in

AH Plus, the pH value was decreasing from 7.4, 7.2 and 6.3 respectively (27). This may be the reason for the higher ALP and OPN expression in Sealapex compared to AH Plus.

Although there was no gene expression in ZOE even on 14<sup>th</sup> day of observation, the genetic markers might be expressed in the latter stages of healing. The possibility of its role in inducing calcification and bone tissue mineralization is not related to its calcium content but may be attributed to its pH which may contribute to its antibacterial activity. Mickel et al. mentioned that the antibacterial activity of a sealer depends on the solubility and physical properties of the antimicrobial component of the sealer (28). ZOE is a water-soluble material. Huang and Kao stated that the pH levels of ZOE cements increased from the 2<sup>nd</sup>, 3<sup>rd</sup> and 4<sup>th</sup> week when immersed in 0.5ml of pH 7.0 buffer solution (29). Furthermore, previous studies reported that when set ZOE is exposed to an aqueous surrounding, Zinc eugenolate is hydrolyzed releasing the free eugenol that even on low concentration can inhibit cell respiration and division (30) (31). This aspect could be the reason of the relatively high antibacterial effect of ZOE.

Each RC sealer has different unique properties that can induce favorable or unfavorable tissue responses. Integrated in the sealers are antimicrobial components that can prevent regrowth of residual bacteria and prevent bacterial re-entry into the RC system (32). Several studies confirmed that various root canal sealers constantly segregate substances after being exposed to an aqueous environment for extended periods (33) (34) which may possibly result in either a beneficial response or a cytotoxic reaction to the periradicular tissues paramount to clinical success. Leonardo et al. (35) confirmed the results obtained in the histopathological analysis of apical and periapical tissues and concluded that RC sealers Sealapex and AH Plus showed satisfactory tissue responses leading to the repair of the apical and periapical regions.

Based on the results, RC sealers AH Plus and Sealapex can induce HPDLF to express calcification markers such as ALP and OPN suggesting that the RC sealers may play a vital role in the healing of the periapical tissue after root canal treatment in initiating calcification.

## REFERENCES

1. Yan MT. The Management of Periapical Lesions in Endodontically Treated Teeth. *Aust Endod J* 2006; 32:2-15.
2. Ørstavik D. Materials Used for Root Canal Obturation: Technical, Biological and Clinical Testing. *Endodontic Topics* 2005; 12: 25v38.
3. Flavell SJ, Hou TZ, Lax S, Filer AD, Salmon M and Buckley CD. Fibroblasts as Novel Therapeutic Targets in Chronic Inflammation. *British Journal of Pharmacology* 2008; 153: S241–S246.
4. Maeda H, Wada N, Nakamuta H and Akamine A. Human periapical granulation tissue contains osteogenic cells. *Cell Tissue Research* 2004; 315: 203-208.
5. Magnusson P, Larsson L, Magnusson M, Davie MWJ and Sharp CA. Isoforms of Bone Alkaline Phosphatase: Characterization and Origin in Human Trabecular and Cortical Bone. *Journal of Bone and Mineral Research* 1999; 14: 1926-33.
6. Denhardt DT and Guo X. Osteopontin: A Protein with Diverse Functions. *Federation of American Societies for Experimental Biology Journal* 1993; 7 (15): 1475-82.
7. Ørstavik D, Kerekes K, Erksen H. Clinical performance of three endodontic sealers. *Endod Dent Traumatol* 1987; 3:178-86.
8. Silva L, Nelson-Filho P, Leonardo MR, Rossi MA, Pansani RA. Effect of calcium hydroxide on bacterial endotoxin in vivo. *J Endod* 2002; 28: 94-98.
9. Sathorn C, Parashos P and Messer H. Antimicrobial Efficacy of Calcium Hydroxide Intracanal Dressing: A Systematic Review and Meta-analysis. *Int Endod J* 2007; 40:2-10.
10. Carvalho-Junior JR, Correr-Sobrinho L, Correr AB, Sinhoreti MA, Consani S, Sousa-Neto MD. Radiopacity of root filling materials using digital radiography. *Int Endod J*. 2007; 40(7): 514-20.
11. Marin-Bauza GA, Rached-Junior FJ, Souza-Gabriel AE, Sousa-Neto MD, Miranda CE, Silva-Sousa YT. Physicochemical properties of methacrylate resin-based root canal sealers. *J Endod*. 2010; 36 (9): 1531-6.
12. Benatti O, Stolf WL and Ruhnke LA. Verification of the Consistency, Setting time, and Dimensional Changes of Root Canal Filling Materials. *Oral Surgery, Oral Medicine, Oral Pathology* 1978; 46: 107-13.
13. Mehran, VM. Antimicrobial Effects of Two Endodontic Sealers and their Cytotoxicity Evaluation 2010; unpublished thesis.
14. Rodriguez A, Inoue M, Tanaka T, Miyake M, Sfer A, Kishimoto E, Tsujigiwa H, Rivera R and Nagatsuka H. Effect of CaTiO<sub>3</sub>-CaCO<sub>3</sub> Prepared by Alkoxide Method on Cell Response. *Journal of Biomedical Materials Research* 2010; 297-303.
15. Nojima N, Kobayashi M, Shionome M, Takahashi N, Suda T, Hasegawa K. Fibroblastic cells derived from bovine periodontal ligaments have the phenotypes of osteoblasts. *J Periodontal Res*. 1990; 25: 179–185.
16. Somerman MJ, Young MF, Foster RA, Moehring JM, Imm G, Sauk JJ. Characteristics of human periodontal ligament cells in vitro. *Arch Oral Biol*. 1990; 35:241–247.
17. Puchtler H, Meloan, SN and Terry M. On the history and Mechanism of Alizarin and Alizarin Red S Stains for Calcium. *The Journal of Histochemistry and Cytochemistry* 1969.17; 2: 110-124.
18. Carlson I, Tognazzi K, Manseau EJ, Dvorak HF, Brown LF. Osteopontin is strongly expressed by histiocytes in granulomas of diverse etiology. *Lab Invest* 1997; 77:103-108.
19. McKee MD, Nanci A. Osteopontin at mineralized tissue interfaces in bone, teeth and osseointegrated implants: Ultrastructural distribution and implications for mineralized tissue formation, turnover and repair. *Microsc Res Technique* 1996; 33:141-164
20. Lekic P, Sodek J, Christopher A, McCulloch CAG. Relationship of cellular proliferation to expression of OPN and bone sialoprotein in regenerating rat periodontium. *Cell Tissue Res* 1996; 285:491–500.
21. Da Silva L, Leonardo M, Silva RD, et al. Calcium hydroxide root canal sealers: evaluation of pH, calcium ion concentration and conductivity. *Int Endod J* 1997; 30: 205-9.

- 
22. Torneck C, Moe H, Howley T. The effect of calcium hydroxide on porcine pulp fibroblasts in vitro. *J Endod* 1983; 9:131 -6.
  23. Schroder U. Effect of calcium hydroxide containing pulp capping agent on pulp cell migration, proliferation and differentiation. *J Dent Res* 1985; 64:541-8.
  24. Das S. Effect of certain dental materials on human pulp in tissue culture. *Oral Surg Oral Med Oral Pathol* 1981; 52: 76-84.
  25. Okabe T, Sakamoto M, Takeuchi H and Matsushima K. Effects of pH on mineralization ability of human dental pulp cells. *J Endod* 2006; 32 (3): 198-201.
  26. Stock C. Calcium hydroxide: root resorption and perio-endo lesions. *Br Dent J* 1985; 158:325-34.
  27. Finger MS, Faraoni G, do Carmo Masson M, dos Santos RAM, Cimardi ACBS and Victorino FR. Comparative evaluation of pH and solubility of MTA Fillapex endodontic sealer. *RSBO* 2014; 11 (1): 41-6.
  28. Mickel A, Nguyen T, Chogle S. Antimicrobial activity of endodontic sealers on *Enterococcus faecalis*. *J Endod* 2003; 29:257-8.
  29. Huang TH and Kao CT. pH Measurement of Root Canal Sealers. *J Endod* 1998; 24 (4): 236-238.
  30. Hume W. Effect of eugenol on respiration and division in human pulp, mouse fibroblasts and liver cells *in vitro*. *J Dent Res* 1984; 63:1262-5.
  31. Markowitz K, Moynihan M, Liu M et al. Biologic properties of eugenol and zinc-eugenol. *Oral Surg Oral Med Oral Pathol* 1992; 73: 729 -37.
  32. Desai S and Chandler N. Calcium Hydroxide-Based Root Canal Sealers: A Review. *J Endod* 2009; 35 (4): 475-80.
  33. Geurtsen W, Leinenbach F, Krage T, Leyhausen G. Cytotoxicity of Four Root Canal Sealers in Permanent 3T3 Cells and Primary Human Periodontal Ligament Fibroblast Cultures. *Oral Surg Oral Med Oral Pathol Oral Radiol Endod* 1998; 85(5): 592-7.
  34. Azar NG, Heidari M, Bahrami ZS and Shokri F. In Vitro Cytotoxicity of a New Epoxy Resin Root Canal Sealer. *J Endod* 2000; 26 (8): 462-5.
  35. Leonardo MR, Salgado AAM, da Silva LAB and Tanomaru-Filho M. Apical and periapical Repair of Dogs' Teeth with Periapical Lesions after Endodontic Treatment with Different Root Canal Sealers. *Pesqui Odontol Bras* 2003; 17(1): 69-74.

#### **Conflict of Interest**

The authors disclosed that there is no conflict of interest.

#### **Acknowledgements**

The authors wish to thank Mr. Glenn Oyong for giving his invaluable assistance in the performance of the experiment, to the Cell and Tissue Culture Laboratory of the Science and Technology Research Center of De La Salle University for providing us with the HPDLF. We wish to thank also Dr. Hitoshi Nagatsuka, Dr. Hidetsugu Tsujigiwa and Dr. Masae Fujii of the Department of Oral Pathology and Medicine, Graduate School of Medicine, Dentistry and Pharmaceutical Sciences, Okayama University, Japan for supplying the Alizarin Red S used in this study. We express our gratitude to Dr. Iluminada L. Vilorio, Dr. Virgilio B. Borja and Dr. Marie Antoniette R. Veluz for sharing the time, knowledge and support in the critical reading of the manuscripts.

#### **About the Authors**

Grace Ellen S. Dey, DMD, MScD  
Associate Professor, Graduate School  
University of the East

Rosario R. Buery, DMD, PhD  
Former Professor, College of Dentistry  
University of the East